

Zainul Amiruddin Zakaria^{1,2*}, Mohammad Hafiz Abdul Rahim¹, Norhafizah Mohtarrudin³, Arifah Abdul Kadir⁴, Manraj Singh Cheema¹, Zuraini Ahmad¹, Ching Siew Mooi⁵ and Siti Farah Md. Tohid¹

¹Department of Biomedical Sciences, Faculty of Medicine and Health Sciences, Universiti Putra Malaysia, 43400 Serdang, Selangor, Malaysia ²Integrative Pharmacogenomics Institute (iPROMISE), Level 7, FF3 Building, Universiti Teknologi MARA, 42300 Puncak Alam, Selangor, Malaysia ³Department of Pathology, Faculty of Medicine and Health Sciences, Universiti Putra Malaysia, 43400 Serdang, Selangor, Malaysia ⁴Department of Veterinary Pre-Clinical Sciences, Faculty of Veterinary Sciences, Universiti Putra Malaysia, 43400 Serdang, Selangor, Malaysia ⁵Department of Family Medicine, Faculty of Medicine and Health Science, Universiti Putra Malaysia, 43400 Serdang, Selangor, Malaysia

Corresponding Author E-mail: zaz@medic.upm.edu.my or dr_zaz@yahoo.com

Abstract

Background: *Clinacanthus nutans* (*C. nutans*) Lindau (family Acanthaceae) is a shrub widely cultivated in the South East Asia region, including Malaysia. It has been traditionally used for treatment of various ailments including pain-mediated diseases. Various pharmacological activities of *C. nutans* have been reported except for its pain-relieving activity. This study was performed to evaluate the acute and sub-chronic oral toxicity of the methanol extract of *Clinacanthus nutans* (MECN) in male and female mice.

Methods: In the acute toxicity study, a single dose of 5000 mg kg⁻¹ of body weight MECN was administered orally, and was monitored for 14 consecutive days. In the sub-chronic toxicity study, the MECN was administered orally at doses of 50, 500, and 2500 mg kg⁻¹ day⁻¹ for 28 days. **Results:** Results showed that there were no clinical signs of toxicity, mortality and body weight changes in both acute and subchronic toxicity studies. There were no significant differences in relative organ weight, haematological parameters, and biochemical parameters; except for the creatinine level, which indicated significant ($p < 0.05$) increase at doses of 500 and 2500 mg kg⁻¹ day⁻¹ for both sexes in the subchronic toxicity study. Necropsy, gross and histopathological observations, did not show any treatment-related signs of toxicity or abnormalities in both the acute and subchronic toxicity studies.

Conclusion: In conclusion, the lethal oral dose (LD₅₀) for the acute toxicity study is greater than 5000 mg kg⁻¹ while for subchronic toxicity study; the no-observed-adverse-effect level (NOAEL) is greater than 2500 mg kg⁻¹ day⁻¹.

Key words: *Clinacanthus nutans*, methanol extract, acute oral toxicity, subchronic oral toxicity, NOAEL, LD₅₀

Introduction

Natural products have been regarded as important sources of medicinal agents for thousands of years due to their potential therapeutic effects as shown by a number of modern drugs which have been isolated from natural sources. Many of these medicinal plants were used in traditional medicine (Preethi et al., 2010; Kiran et al., 2011; Khera et al., 2012). World Health Organization (WHO) estimated of about 80% of the world's inhabitants depends mainly on traditional medicine for their primary health care (Verma and Singh, 2008; Cheikhoussef et al., 2011; Dey et al., 2012). Medicines made out of natural products derived from a variety of sources; including terrestrial plants, terrestrial microorganisms, marine organisms, terrestrial vertebrates and invertebrates (Rout et al., 2009). The value of natural products becomes particularly obvious, considering the rate of introduction of new chemical entities with significant structural diversity, including templates for semi-synthetics and total synthetics modification (Golvez-Llompart et al., 2011).

Clinacanthus nutans (*C. nutans*) Lindau locally known as 'belalai gajah' belongs to the family of Acanthaceae. *C. nutans* is a shrub with short hair branches, the leaves are in pairs of opposite arrangement, narrowly elliptic-oblong in shape and pale green in colour. Furthermore, it has small, soft, thin and slightly curved stem that resembles the curve of an elephant's trunk. In South East Asia, particularly in Indonesia, Malaysia and Thailand; the plant has traditionally been used for treatment of mental stress, diabetes, fever, dysentery, burns, scalds, herpes skin infections, diarrhoea, analgesics, rheumatoid arthritis and snake bite (Wanikiat et al., 2008; P'ng et al., 2012a; Kunsorn et al., 2013; Shim et al., 2013; Yang et al., 2013). In recent years, several studies on the aspect of *C. nutans* pharmacological properties such as antiviral, immune response, anti-inflammatory and anti-proliferative activities (Sriwanthana et al., 1996; Wanikiat et al., 2008; Sakdarat et al., 2009; Yong et al., 2013). The *C. nutans* also possessed anti-herpes simplex virus, antimutagenic as well as antioxidant activities (Pannangpetch et al., 2009; Rathnasamy et al., 2009; Kunsorn et al., 2013). Moreover, it can act as an anti-varicella-zoster virus, and has been tested in clinical trial for the treatment of recurrent aphthous ulcer (Timpawat and Vajrabhaya, 1994; Sangkitporn et al., 1995).

Phytochemical constituents are chemical compounds formed during the plant's normal metabolic processes. These chemicals

are often referred to as “secondary metabolites”, of which consists of several classes including alkaloids, flavonoids, coumarins, glycosides, gums, polysaccharides, phenols, tannins, terpenes and terpenoids (Jegadeeswari et al., 2012; Mithraja et al., 2012). Most of these phytochemical constituents are potent bioactive compounds originated from plant, which are precursors for the synthesis of many useful drugs (Kalpana et al., 2012; Aziagba et al., 2013). Several phytochemicals have been isolated and their chemical compositions have been characterized from various parts and extracts of *C. nutans*; such as flavonoids, stigmaterol, lupeol, β -sitosterol, betulin, C-glycosyl flavones, vitexin, isovitexin, shaftoside, isomollupentin-7-*O*- β -glucopyranoside, orientin, isoorientin, sulfur-containing glucosides, cerebrosides, monoacylmonogalactosylglycerol, diterpenes, phytosterols, flavonoids, and saponins, (Wanikiat et al., 2008; Pannangpetch et al., 2009; Rathnasamy et al., 2009; Yang et al., 2013) which have been proven to possess various pharmacological activities.

Toxicity is the degree to which a substance causes damage towards an organism. In this case, toxicity refers to the effect on a whole organism (*i.e.* an animal, bacterium or plant) as well as the effect on substructure of the organism (*i.e.* a cell, an organ such as liver, kidney, heart). Besides that, they are metaphorically used to describe the toxic effects on larger and more complex groups, such as a family unit or a community (Auwal et al., 2012; Bahar et al., 2013). Therefore, this study was performed to evaluate the safety of methanol extract from the *C. nutans* (MECN) leaves, according to the acute and 28 days subchronic toxicity in experimental animals. Additionally, qualitative chemical tests were performed to identify numerous phytochemical constituents of this extract.

Materials and Methods

Plant Material and Extraction

Fresh leaves of *C. nutans* were purchased from a local supplier. Extraction was carried out according to the method described by Zakaria et al. (2011a). In order to obtain the MECN, 250 g of the leaves were dried in an oven at 40°C for 1 – 2 days. Then the leaves were grinded into powder using an electric grinder (RT-08, Rong Tsong Precision Technology Co., Taiwan). The powder was soaked in methanol (Fisher Scientific, UK) with the ratio of 1:20 (w/v) for 72 hours at room temperature. This is followed by the methanol supernatant being filtered sequentially using cloth filter, cotton wool and Whatman no. 1 filter paper (Sigma-Aldrich, St. Louis, USA).

The residue was collected and subjected to the same techniques for another additional two cycles. The methanol supernatant collected from each cycle was pooled together and then subjected to an evaporation process using a vacuum rotary evaporator (Hei-vap value, Heidolph, Germany) at 40°C under a reduced pressure. The end product is approximately 53 g of dried MECN (percentage yielded was 21.2% (w/w)). The extract obtained was stored at 4°C until use.

Phytochemical Screening

The MECN is subjected to phytochemical tests for the presence of alkaloids, saponins, flavanoids, tannins, triterpenes and steroids according to the method described by Zakaria et al. (2011b) and Mamat et al. (2013).

Experimental Animals

Male and female ICR mice weighing between 25-30 g (5-7 weeks old) obtained from the Animals Source Unit, Faculty of Veterinary Medicine (FVM), Universiti Putra Malaysia (UPM), were used for acute and subchronic toxicology studies. The animals were kept under room temperature ($27 \pm 2^\circ\text{C}$; 70-80% humidity; 12-hour light/dark cycle) in the Animal Holding Unit, Faculty of Medicine and Health Sciences (FMHS), UPM for at least 48 hours prior to the procedure. A commercial food pellets (Gold Coin Sdn. Bhd., Port Klang, Malaysia) and water were supplied *ad libitum* from the beginning of the experiments. The animal experimental procedures were performed according to Universiti Putra Malaysia's animal ethics guidelines (UPM/IACUC/AUP-R032/2013).

Acute Oral Toxicity Study

A 14-day acute oral toxicity study was carried out according to the Organization for Economic Cooperation and Development (OECD) guidelines 425 (OECD, 2008a) with some modification. The mice were divided into two groups: a control group and a treatment group ($n = 10$; 5 males and 5 females). The MECN was dissolved in 10% dimethyl sulfoxide (DMSO; Fisher Scientific, UK) and administered orally at a single dose of 5000 mg kg⁻¹ body weight, while the control group received only the vehicle. Mice were fasted prior to conducting the experiment (only food but not water was withheld for 4 hours). Following the period of fasting, the mice were weighed and the test substance was administered orally at a single dose, after which the food may be withheld for a further 1-2 hours. A dose of 5000 mg kg⁻¹ body weight was given to the first mouse, then the clinical signs (changes in physical appearance, skin, pain, stress, abdominal contraction) and mortality were observed throughout the first hour, then every hour for 3 hours and finally periodically until 48 hours. If the animal survived, four additional animals will be given the same 5000 mg kg⁻¹ dose sequentially at 48 hours intervals. All of the experimental animals were monitored for apparent signs of toxicity for the 14 consecutive days, while the number of died mice within the study period was noted and subjected to necropsies.

All mice were weighted (CPA224s, Sartorius, Geottingen, Germany) and sacrificed on the 15th day after administration, and the selected organs (heart, kidney, liver, lung and spleen) were then secured in 10% formalin (Fisher Scientific, UK) for histopathological examination. The LD₅₀ value was predicted to be above 5000 mg kg⁻¹ if three or more mice survived.

Subchronic Oral Toxicity Study

A 28-day subchronic oral toxicity was performed following OECD guidelines 407, which is the repeated dose of 28-day procedure for chemical testing (OECD, 2008b). The mice were divided into four groups ($n = 10$; 5 males and 5 females per group), and their weights were measured. The MECN was dissolved in 10% DMSO, and administered orally at single doses of 50, 500 and 2500 mg $\text{kg}^{-1} \text{day}^{-1}$ for 28 days, at a dosing volume of 10 mL kg^{-1} body weight, while the control group received only the vehicle. The animals were observed daily for their physiological and behavioural changes (*i.e.* signs of toxicity, mortality and the body weight changes). The body weights of the animals were recorded once a week throughout the study period. At the end of the treatment, the animals were anaesthetized with diethyl ether (Fisher Scientific, UK) following 12 hours of fasting. Blood samples were obtained through cardiac puncture, transferred into EDTA-containing and non-heparinized tubes. Blood with EDTA-containing tube was used immediately for haematological parameters while for non-heparinized tube, it was allowed to clot under room temperature for 15-30 minutes before being centrifuged at $3000 \times g$ at 4°C for 10 min using a centrifuge machine (Universal 320R, Hettich, Germany). The serum obtained was stored at -20°C until further analysis of biochemical parameters (Hor et al., 2011; 2012).

After the cardiac puncture procedure, the animals were then sacrificed by cervical dislocation while organs such as spleen, heart, liver, sex organs (testes in male; ovaries of female), kidneys, lungs, stomach and brain were removed, rinsed in 0.9% saline and weighed individually. The relative organ weight (ROW) for each organ being determined using the following formula; Relative organ weight = (Absolute organ weight (g)/body weight of mice on the day of sacrifice (g)) \times 100% (Rajeh et al., 2012). The selected organs (heart, kidney, liver, lung and spleen) were then secured in 10% formalin for histopathological examination.

Haematological and Biochemical Analysis

Haematology and biochemical analysis were performed at the Haematology and Clinical Biochemistry Laboratory, FVM, UPM. The haematological parameters, which comprised of haemoglobin (Hb), total red blood cell (RBC) count, packed cell volume (PCV), mean corpuscular volume (MCV), mean corpuscular haemoglobin concentration (MCHC), total white blood cell (WBC) count, neutrophils, monocytes, eosinophil and platelet counts were performed using an automated haematology analyser (Cell-Dyn 3700, Abbot Diagnostics, USA).

The biochemical analysis tests were performed using an automated chemistry analyser (Hitachi 902, Tokyo, Japan), for biochemical enzymes' level (*i.e.* alanine aminotransferase (ALT), albumin, alkaline phosphatase (ALP), aspartate aminotransferase (AST), creatinine, total bilirubin, total protein and urea).

Histopathological Studies

Histopathology studies were done at the Histopathology Laboratory, FMHS, UPM. All the selected vital organs (heart, kidney, liver, lung and spleen) were washed with cold normal saline and fixed in 10% formalin for at least 48 hours. After fixation, the organs were trimmed at 5 mm thickness and placed in plastic cassettes, before being processed using a standard overnight method in an Automatic Tissue Processor (Leica TP1020, Germany). After processing, the tissues were embedded in paraffin with Leica EG 1160 (Leica Microsystems, Germany) and then sectioned to a thickness of 5 μm using a rotary microtome (Leica RM2135, Germany). The tissue sections were placed in a water bath (Leica H1210, Germany) at 35°C to 37°C , and were then mounted on glass slides using a slide warmer (Lab-line Instruments, model 26007, Melrose Park, USA), and stained with Haematoxylin and Eosin (H&E) stain, by using Tissue-Tek Prisma-Ezs Autostainer (Sakura, Torrance, CA) (Tubasha et al., 2013). The tissues were then examined under Olympus-CX31 light microscope (Olympus, Japan).

Statistical Analysis

Statistical analysis was performed using the GraphPad Prism version 5.00 for Windows (GraphPad Software, San Diego California USA). Data were expressed as the mean \pm standard error of mean (S.E.M). The mean differences between the control and treatment groups were determined using one-way analysis of variance (ANOVA) with Dunnett's post hoc tests. A p value <0.05 was considered statistically significant.

Results

Phytochemical Screening of MECN

The phytochemical screening of MECN has demonstrated the presence of flavonoids, saponins, steroids and triterpenes, but not alkaloids and tannins (Table 1).

Acute Oral Toxicity study

All the male and female animals that were administered with a single oral dose of 5000 mg kg^{-1} body weight of MECN, has survived 14 days of the acute oral toxicity experiment and did not show any changes in clinical signs of toxicity either immediately following dosing or during the observation period of 14 days. There were no significant differences in body weight between the control

and treatment for both male and female groups (Figure 1). The calculated acute oral toxicity (LD_{50}) value of MECN for male and female mice was predicted to be greater than 5000 mg kg^{-1} . Hence, the observation from the oral acute toxicity study suggests that the MECN is safe for oral administration.

Subchronic Oral Toxicity Study

The determination of subchronic oral toxicity of the MECN was performed following oral administration at single doses of 50, 500 and $2500 \text{ mg kg}^{-1} \text{ day}^{-1}$ for 28 days. There were no significant changes in clinical signs of toxicity and mortality observed in either sexes in the control and the MECN groups at any doses up to $2500 \text{ mg kg}^{-1} \text{ day}^{-1}$ either, immediately following dosing or during the 28 days observation period. The effects on body weight of both male and female mice during 28 days the treatment of MECN are stated in Table 2. There were no significant difference in body weight between the control and any of the MECN treated groups during the study period. Similar results were obtained for the relative organ weight of brain, heart, kidneys, liver, lung, spleen, stomach and testes/ovaries, where there were no significant differences between both sexes in the control and the MECN-treated groups (Table 3).

Haematological and Biochemical Analysis

The effect of subchronic oral toxicity of the MECN on the haematological parameters is stated in Table 4. The haematological parameters [*i.e.* eosinophils, haemoglobin (Hb), mean corpuscular haemoglobin concentration (MCHC), mean corpuscular volume (MCV), monocytes, neutrophils, packed cell volume (PCV), platelet count, total red blood cell (RBC) and total white blood cell (WBC)] showed no significant differences in either sexes in any of the MECN-treated groups (at doses of 50, 500, and $2500 \text{ mg kg}^{-1} \text{ day}^{-1}$) as compared to the control groups during the study period (Table 4). The biochemical parameters of the MECN-treated and control groups are as listed in Table 5. There was a significant increase in creatinine level in mice at the doses of 500 ($p < 0.01$) and 2500 ($p < 0.001$) $\text{mg kg}^{-1} \text{ day}^{-1}$ for both sexes, as compared to the control groups. The other biochemical parameters (*i.e.* albumin, ALP, ALT, AST, total bilirubin, total protein and urea) did not show any significant changes during the treatment period (Table 5).

Histopathological Study

Macroscopic observations in treated animals at necropsy did not show any treatment-related injury or any gross abnormalities that may be attributed to the acute and subchronic toxicity. The histopathological analysis of the selected organs (heart, kidney, liver, lung and spleen) in both the acute and subchronic toxicity studies demonstrated that there were no lesions or sign of pathological changes signifying abnormalities in either sexes of the treatment groups or their respective control groups (Figure 2 and Figure 3).

Discussion

In this study, we have demonstrated the safety profile of the MECN in the acute and subchronic toxicity study in male and female ICR mice, along with the evaluation of preliminary phytochemical constituents of the MECN.

Phytochemical constituents have received extensive attention in recent years due to their pharmacological potency and there is need to explore their therapeutic potential. Several classes of compounds derived from various extracts of *C. nutans* have been identified, isolated and proven to possess diverse pharmacological activities (Wanikiat et al., 2008; Pannangpetch et al., 2009; Rathnasamy et al., 2009; Yang et al., 2013). Preliminary phytochemical analysis of the MECN in this study showed the presence of flavonoids, saponins, steroids and triterpenes. In terms of pharmacological properties, these compounds (*i.e.* flavonoids, saponins and triterpenes), have been reported to elicit anti-allergic, anticancer, anticarcinogenic, antidiarrhoeal, antihepatotoxic, anti-inflammatory, antimicrobial, antinociceptive, antioxidant, antioxytotoxic, antiulcerogenic, anti-ulcer, antiviral, hepatoprotective, hypoglycemic, immunostimulant and neuroprotective activities (Lacaille-Dubois and Wagner, 1996; Toker et al., 2004; Akachi et al., 2010; Agrawal, 2011; Czaplinska et al., 2012; Mandegary et al., 2012; Raihan et al., 2012; Ai et al., 2013; Mamat et al., 2013; Negi et al., 2013; Yahya et al., 2013). Steroids on the other hand, have been reported to have antibacterial properties, anti-inflammatory activities, cardiotoxic activities, possess insecticidal and antimicrobial properties, analgesic properties, and also central nervous system activities (Yadav and Agarwala, 2011; Kalaivani et al., 2013; Maobe et al., 2013; Gauniyal and Teotia, 2014).

Data from the acute toxicity study may (a) serve as the basis for classification and labelling; (b) provide initial information on the mode of toxic action of a substance; (c) achieve a dosage volume of a new compound; (d) aid in dosage determination in animal studies; and (e) assist to determine LD_{50} value that will provide many indices of potential types of drug activity (Bhardwaj and Gupta, 2012; Chaudhary and Krishnaraju, 2012; Ukwuani et al., 2012). The results of the oral acute administration of the MECN with the dosage up to 5000 mg kg^{-1} did not produce any treatment-related signs of toxicity or mortality during 14 days of the study period. In this study, regardless of the dosage used, the MECN did not give rise to any significant changes in mice general behaviours, body weight, gross or histopathological examination of internal organs. Previous toxicological study reported the acute toxicity of ethanolic extract of *C. nutans* leaves did not manifest any significant visible signs of toxicity in the animals at doses up to 1300 mg kg^{-1} (Chavaluttrumong et al., 1995), whereas investigation of the acute oral toxicity of methanolic leaves extract of *C. nutans* suggested that the LD_{50} value to be greater than 1800 mg kg^{-1} with no sign of toxicity (P'ng et al., 2012a). Meanwhile, this study indicates the LD_{50} value to be above 5000 mg kg^{-1} upon oral administration. Both studies indicate no mortality with doses up to 5000 mg kg^{-1} body weight. Based on the OECD guidelines 425 Up-and-Down procedures for testing of chemicals (OECD, 2008a), this finding indicates that the MECN is classified as category 5,

which has relatively low acute toxicity hazard. On the other hand, according to another guideline of toxicity classification, biochemical substances with LD₅₀ between 500 to 5000 and 5000 to 15,000 mg kg⁻¹ are categorized as slightly toxic and practically non-toxic, respectively (Loomis and Hayes, 1996). Hence, the MECN, with oral administration of a single dose of 5000 mg kg⁻¹ is non-toxic.

The subchronic studies evaluate the adverse effects of continuous or repeated exposure of substance over a portion of the average life span of experimental animals. In this case, it provides the information on the target-organ toxicity and bioaccumulation potential, which are designed to determine the no-observed-adverse-effect levels (NOAELs), used to establish the standards or guidelines for human exposure. Moreover, subchronic studies are not designed to assess long term effects such as cancer, but it does offer the information that can be used in setting up the doses for the chronic toxicity and carcinogenicity studies (NRC, 2006). The 28 days continual dose of the MECN oral toxicity study indicates that the doses of 50, 500 and 2500 mg kg⁻¹ day⁻¹ did not produce any changes in the mice's general behaviours, treatment-related signs of toxicity or mortality. These results are in agreement with those reported earlier for subchronic oral toxicity studies of methanol extract of *C. nutans*, that reported doses up to 1300 mg kg⁻¹ day⁻¹ did not produce any significant visible signs of toxicity in rats (P'ng et al., 2012b). The reduction in body weight exceeding 10% of initial body weight and internal organ weights are considered as a simple and sensitive index of toxicity following exposure to potentially toxic substances (Teo et al., 2002; Rajeh et al., 2012). In this study, the body weight of MECN treated groups did not show any significant changes from that of the control groups. In addition, the internal organ weight is an important index of physiological status in animals. The relative internal organ weight is fundamental in order to diagnose whether the organ suffered any treatment related injury. In drug metabolism context, the heart, liver, kidney, spleen and lungs are the primary organs that will be affected by metabolic reactions in the presence of toxicants (Jothy et al., 2011; Vaghasiya et al., 2011). The present study revealed that the relative organ weights in all the MECN-treated groups in both sexes did not show any significant difference from the control groups, signifying that the MECN was non-toxic.

The haematopoietic system serves as an important target for toxic chemicals and it is a sensitive index for physiological and pathological status in humans and animals (Kulkarni and Veeranjanyulu, 2012). The analysis of blood parameters is relevant for risk evaluation, as any changes in haematological system is a great predictive value for human toxicity, when the data are extrapolated from animal studies (Chandra et al., 2012). This present study indicated that there were no significant alterations in haematological parameters (*i.e.* eosinophils, Hb, MCHC, MCV, monocytes, neutrophils, PCV, platelet count, RBC and WBC) between the control and treated groups for both sexes, demonstrating that the MECN did not affect haematopoiesis and leucopoiesis in mice. The haematopoiesis is a process of formation of blood cellular components, while leukopoiesis is a form of haematopoiesis in which white blood cells are formed in bone marrow of adults' bones and haematopoietic organs in the foetus (Hor et al., 2011). In these cases, the extract was non-toxic and did not affect the production of circulating red blood cells, white blood cells or platelets. This was further confirmed with gross necropsy observations, which showed no injuries to any haematopoietic organs and no related changes in the histopathology findings.

Monitoring the concentrations of serum liver enzymes (*i.e.* ALT, AST and ALP) is important as it helps to detect chronic liver diseases and reflect the status of liver injury (Hor et al., 2012; Gad et al., 2013). Alanine Aminotransferase (ALT) is a cytoplasmic enzyme that is found at a very high concentration in the liver, and an increase of this enzyme level suggests hepatocellular damage. Aspartate Aminotransferase (AST) is found in the cytoplasm and mitochondria of different tissues; including the liver, heart, skeletal muscles, kidney and brain (Gad et al., 2013; Ekeanyanwu and Njoku, 2014), while Alkaline phosphatase (ALP) is a hydrolase enzyme that is found in the cells throughout the body, but is significantly higher in biliary ducts, liver, bone, placenta, kidney and intestine (Singh et al., 2011). In addition, bilirubin elevation and albumin reduction serve as confirmatory markers for varying liver function (Rasekh et al., 2008). A small elevation in serum bilirubin is an important sign of liver damage or a signal of biliary duct obstruction. An increase in the level of serum proteins is a sign of tissue injury (Solomon et al., 1993). The determination of serum proteins such as albumin can act as a criterion to assess the synthetic capacity of the liver, since nearly all are synthesized in hepatocytes. A reduction in serum proteins therefore tends to reflect an occurrence of a chronic damage (Rasekh et al., 2008). In this study, there were no significant differences in the level of AST, ALT, ALP, bilirubin and total protein between the control and treated groups at all tested doses. These imply that the MECN did not cause damage to the liver. This was further verified by histopathological examination of the liver that showed normal liver architecture in all groups and doses.

Blood urea and creatinine levels are tested to evaluate renal dysfunction and failure (Ekeanyanwu and Njoku, 2014). An upsurge in the blood creatinine level is associated with negative impact on kidney function or impaired glomerular filtration (Hor et al., 2012; Gad et al., 2013). Likewise, a hike in blood serum urea signal a toxic effect on the renal tubules, renal parenchyma, cardiac injury and blockage of the urinary outflow track by crystalluria, calculi or other obstructions (Evan, 2010). The current results showed that the creatinine level increase significantly in the 500 and 2500 mg kg⁻¹ day⁻¹ MECN treated groups in both sexes compared to the control groups. Nevertheless, these significant changes were within normal laboratory range and were not considered as a sign of nephrotoxicity (Evan, 2010). On the other hand, the data of blood serum urea denoted that there was no significant difference as compared to the control groups. Hence, the MECN did not cause nephrotoxicity. This was further supported by the histopathological analysis and microscopic examination of the kidneys, showing normal architecture.

The macroscopic examinations of the organs of animals treated with various doses of MECN did not show any changes in colour compared to the control groups. The histopathological studies serve as a supportive evidence for haematological and biochemical analysis (Ramswamy et al., 2012). This study showed that the selected organs obtained from both treated animals and controls showed normal architecture, suggesting that there were no detrimental changes or morphological disturbances caused by daily oral administration of the MECN. Hence, these results strongly suggest that the MECN did not alter the liver or renal function and further validated the non-toxic nature of *C. nutans* extract.

Since the oral administration of MECN at a dose of 2500 mg kg⁻¹ day⁻¹ for 28 consecutive days for both male and female mice did not produce any treatment-related signs of toxicity in their general behaviour, body weight gain, relative organ weights, haematology, biochemical, gross and histopathological examinations suggest that the dose could be categorized as NOAELs for both male and female

animals in this study. According to the above investigation, the NOAEL of MECN for mice can be considered as greater than 2500 mg kg⁻¹ day⁻¹ under the condition of this investigation.

In conclusion, the acute and subchronic toxicity studies showed no treatment-related signs of toxicity or mortality and no significant changes in the body weight gain. Subchronic toxicity did not induce any biochemical, haematological, anatomical and histopathological signs of toxicity. Therefore, the LD₅₀ for the acute toxicity study was greater than 5000 mg kg⁻¹ while for the subchronic toxicity study and the NOAEL was greater than 2500 mg kg⁻¹ day⁻¹.

Declaration of Conflict of Interest: The authors declare no conflict of interest.

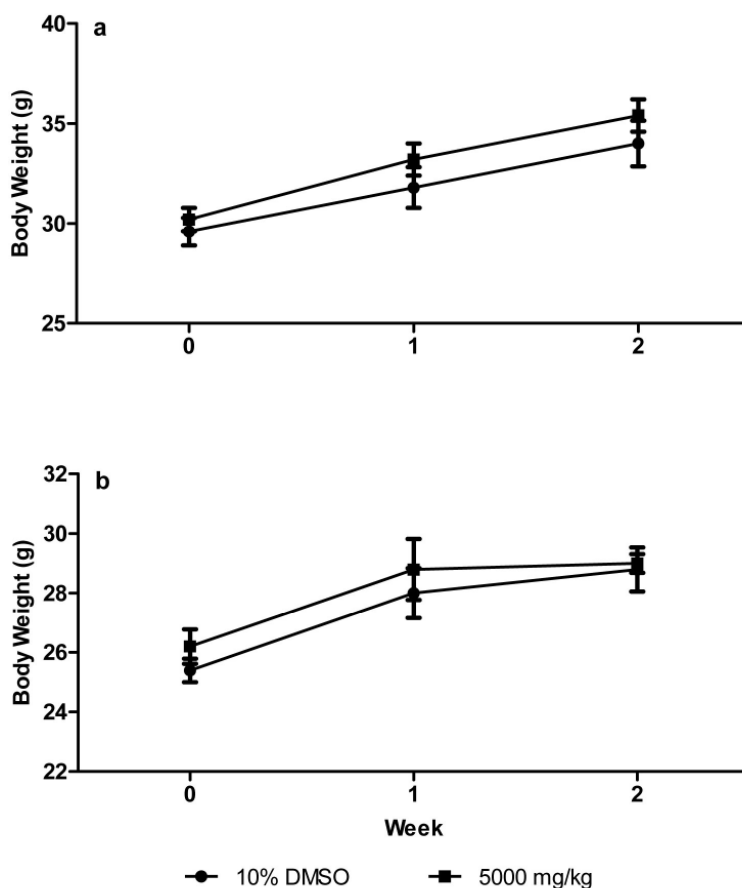


Figure 1: Effects of methanol extract of *C. nutans* on body weight of male (a) and female (b) ICR mice in acute oral toxicity study. Values are expressed as mean \pm S.E.M. ($n=5$ /group).

Table 1: Phytochemical constituents of methanol extract of *C. nutans*

Chemical constituents	MECN
Alkaloids	-
Flavonoids	+
Saponins	+
Steroids	+++
Tannis	-
Triperpenes	+

For alkaloids, +: negligible amount of precipitate; ++: weak precipitate; +++: strong precipitate.

For saponins, +: 1 – 2 cm froth; ++: 2 - 3 cm froth; +++: >3cm froth.

For flavonoids, Steroids, Tannis, and Triterpenes, +: weak colour; ++: mild colour; +++: strong colour.

Table 2: Effects on body weight of male and female ICR mice in 28-days treatment of methanol extract of *C. nutans*.

Body Weight (g)	Male				Female			
	Control	MECN (mg kg ⁻¹ day ⁻¹)			Control	MECN (mg kg ⁻¹ day ⁻¹)		
		50	500	2500		50	500	2500
Week 1	31.80 ± 0.58	33.00 ± 0.55	33.20 ± 0.58	33.00 ± 1.14	28.40 ± 0.51	27.40 ± 0.68	28.80 ± 0.80	28.40 ± 0.93
Week 2	33.20 ± 1.07	32.60 ± 1.91	35.20 ± 0.73	34.60 ± 1.25	29.40 ± 0.98	27.80 ± 0.49	29.20 ± 0.73	28.20 ± 1.02
Week 3	33.20 ± 1.49	33.00 ± 1.51	35.80 ± 0.80	35.20 ± 0.80	31.60 ± 1.50	30.80 ± 0.58	30.20 ± 0.73	29.00 ± 0.89
Week 4	34.20 ± 1.24	33.80 ± 1.66	36.80 ± 1.02	35.20 ± 1.07	30.40 ± 1.44	30.40 ± 0.51	29.80 ± 0.58	28.80 ± 1.36

Values are mean ± S.E.M., n = 5.

Table 3: Effects on relative organ weight of male and female ICR mice in 28-days treatment of methanol extract of *C. nutans*.

Organ	Male				Female			
	Control	MECN (mg kg ⁻¹ day ⁻¹)			Control	MECN (mg kg ⁻¹ day ⁻¹)		
		50	500	2500		50	500	2500
Brain	1.16 ± 0.14	1.29 ± 0.05	1.42 ± 0.07	1.39 ± 0.05	1.62 ± 0.14	1.52 ± 0.12	1.73 ± 0.04	1.85 ± 0.11
Heart	0.47 ± 0.03	0.54 ± 0.05	0.49 ± 0.03	0.51 ± 0.03	0.47 ± 0.04	0.47 ± 0.03	0.47 ± 0.02	0.51 ± 0.03
Kidney (Left)	0.74 ± 0.04	0.70 ± 0.04	0.62 ± 0.02	0.79 ± 0.06	0.64 ± 0.02	0.64 ± 0.02	0.56 ± 0.04	0.69 ± 0.03
Kidney (Right)	0.73 ± 0.02	0.71 ± 0.05	0.62 ± 0.03	0.75 ± 0.05	0.63 ± 0.03	0.63 ± 0.04	0.55 ± 0.03	0.68 ± 0.02
Liver	5.35 ± 0.18	5.32 ± 0.22	4.88 ± 0.17	5.79 ± 0.14	4.55 ± 0.08	5.21 ± 0.42	4.45 ± 0.14	5.33 ± 0.22
Lung	0.85 ± 0.04	0.87 ± 0.07	0.84 ± 0.03	0.76 ± 0.13	0.87 ± 0.08	0.86 ± 0.05	0.84 ± 0.05	1.02 ± 0.09
Spleen	0.62 ± 0.09	0.53 ± 0.07	0.40 ± 0.01	0.44 ± 0.06	0.50 ± 0.01	0.57 ± 0.04	0.52 ± 0.05	0.62 ± 0.05
Stomach	0.95 ± 0.04	1.18 ± 0.08	1.04 ± 0.05	1.09 ± 0.07	1.19 ± 0.09	1.18 ± 0.05	1.18 ± 0.05	1.28 ± 0.05
Testicle/Ovary (Left)	0.30 ± 0.02	0.36 ± 0.02	0.29 ± 0.01	0.34 ± 0.01	0.02 ± 0.01	0.02 ± 0.01	0.03 ± 0.01	0.02 ± 0.01
Testicle/Ovary (Right)	0.32 ± 0.02	0.34 ± 0.02	0.29 ± 0.01	0.32 ± 0.02	0.03 ± 0.01	0.02 ± 0.01	0.03 ± 0.01	0.03 ± 0.01

Values are mean ± S.E.M., n = 5.

Table 4: Effects on haematological parameters of male and female ICR mice in 28-days treatment of methanol extract of *C. nutans*

Parameters	Male				Female			
	Control	MECN (mg kg ⁻¹ day ⁻¹)			Control	MECN (mg kg ⁻¹ day ⁻¹)		
		50	500	2500		50	500	2500
Eosin (%)	3.20 ± 1.28	2.60 ± 0.51	2.60 ± 0.93	2.40 ± 0.51	3.40 ± 0.75	2.60 ± 0.40	2.00 ± 0.45	3.80 ± 0.86
Hb (g/L)	132.0 ± 4.15	138.8 ± 4.53	142.8 ± 3.73	139.4 ± 3.59	138.4 ± 3.06	141.2 ± 2.87	149.0 ± 2.17	125.2 ± 5.72
MCHC (g/L)	379.0 ± 3.27	385.2 ± 2.15	377.4 ± 4.51	379.0 ± 7.42	382.8 ± 7.81	387.8 ± 3.25	380.8 ± 6.18	371.0 ± 6.49
MC V (fL)	43.40 ± 0.60	43.60 ± 0.93	43.80 ± 0.73	44.40 ± 0.51	43.40 ± 0.51	43.80 ± 0.92	44.00 ± 0.84	43.40 ± 1.17
Mono (%)	6.20 ± 0.73	6.80 ± 0.58	7.80 ± 0.49	5.20 ± 0.37	5.00 ± 0.55	6.60 ± 0.67	5.80 ± 0.97	4.80 ± 0.86
Neut (%)	3.4 ± 0.68	3.2 ± 0.58	2.4 ± 0.25	2.8 ± 0.59	1.80 ± 0.20	2.60 ± 0.51	1.80 ± 0.37	1.40 ± 0.40
PCV (L/L)	0.35 ± 0.01	0.36 ± 0.01	0.38 ± 0.01	0.37 ± 0.01	0.36 ± 0.01	0.36 ± 0.01	0.39 ± 0.01	0.34 ± 0.02
Plts (10 ⁹ /L)	751.4 ± 35.44	889.0 ± 63.84	806.4 ± 39.69	838.0 ± 62.28	645.0 ± 59.62	675.6 ± 62.87	725.8 ± 53.34	553.4 ± 117.1
RBC (10 ¹² /L)	8.03 ± 0.25	8.29 ± 0.39	8.64 ± 0.23	8.28 ± 0.24	8.36 ± 0.22	8.34 ± 0.27	8.88 ± 0.15	7.81 ± 0.34
WB C (10 ⁹ /L)	9.34 ± 4.34	7.08 ± 0.88	3.36 ± 0.62	7.58 ± 1.56	3.74 ± 0.40	3.9 ± 0.32	2.22 ± 0.37	3.20 ± 0.90

Values are mean ± S.E.M., n = 5.

Abbreviations: Eosin, Eosinophils; Hb, haemoglobin; Alb, albumin; ALP, alkaline phosphatase ; ALT, alanine aminotransferase; AST, aspartate aminotransferase; Creat, creatinine; T Bil, total bilirubin; T Prot, total protein

Table 5: Effects on biochemical parameters of male and female ICR mice in 28-days treatment of methanol extract of *C. nutans*

Parameters	Male				Female			
	Control	MECN (mg kg ⁻¹ day ⁻¹)			Control	MECN (mg kg ⁻¹ day ⁻¹)		
		50	500	2500		50	500	2500
Alb (g/L)	31.14 ± 1.14	33.16 ± 1.24	33.72 ± 0.36	32.6 ± 0.56	33.24 ± 3.16	39.14 ± 0.81	38.58 ± 1.12	36.54 ± 0.59
ALP (U/L)	85.0 ± 19.02	57.0 ± 6.21	109.0 ± 15.22	82.60 ± 6.18	154.8 ± 23.6	139.8 ± 28.8	111.4 ± 9.85	126.4 ± 16.3
ALT (U/L)	75.98 ± 23.94	64.06 ± 6.02	66.2 ± 7.91	55.02 ± 4.75	83.44 ± 21.1	105.6 ± 25.5	62.44 ± 7.49	63.20 ± 13.3
AST (U/L)	352.4 ± 78.3	274.1 ± 45.8	213.2 ± 39.2	204.9 ± 17.9	352.4 ± 78.3	258.8 ± 51.6	282.9 ± 87.4	291.9 ± 59.1
Creat (umol/L)	32.6 ± 0.87	32.0 ± 1.98	41.8 ± 0.96 *	40.6 ± 2.16 *	33.60 ± 1.36	31.20 ± 1.46	46.80 ± 1.32 **	47.8 ± 2.08 **
T Bil (umol/L)	3.58 ± 1.22	1.94 ± 0.74	3.84 ± 0.52	2.38 ± 0.89	0.80 ± 0.39	2.12 ± 0.44	2.14 ± 0.59	1.70 ± 0.67
T Prot (g/L)	61.54 ± 2.64	56.74 ± 2.42	55.46 ± 0.76	54.32 ± 1.85	56.90 ± 4.69	57.38 ± 2.08	55.66 ± 0.77	56.36 ± 0.65
Urea (mmol/L)	10.10 ± 1.06	12.74 ± 0.84	9.92 ± 0.18	11.70 ± 0.95	8.64 ± 0.58	10.36 ± 0.30	7.36 ± 0.85	10.72 ± 0.75

Values are mean ± S.E.M., n = 5.

Abbreviations: Alb, albumin; ALP, alkaline phosphatase ; ALT, alanine aminotransferase; AST, aspartate aminotransferase; Creat, creatinine; T Bil, total bilirubin; T Prot, total protein
Significantly different from control: *p < 0.01, ** p < 0.001

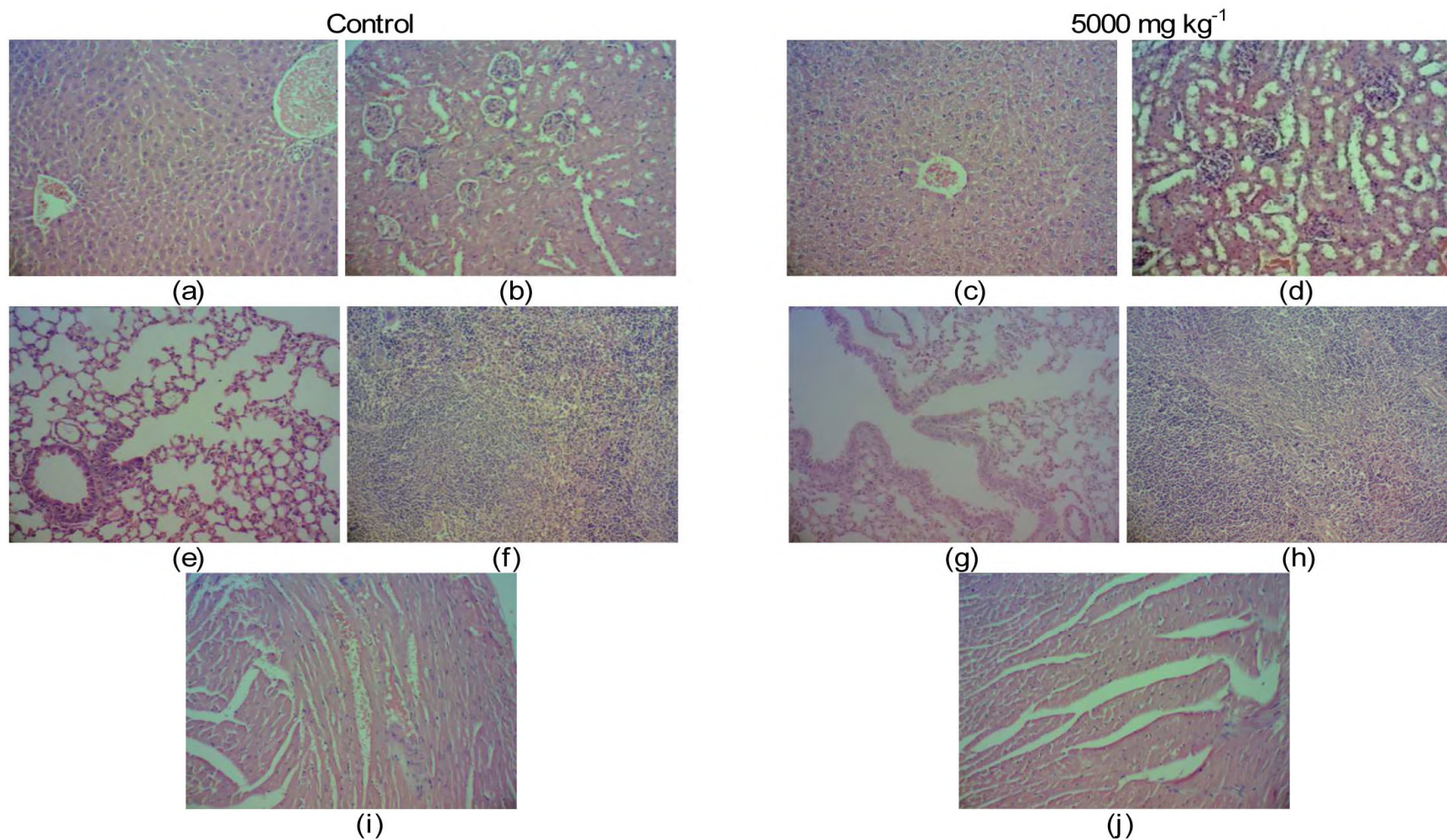


Figure 2: Photomicrographs of histopathology from representative female ICR mice in acute oral toxicity: (a), and (c): liver; (b), and (d): kidney; (e), and (g): lung; (f), and (h): spleen; (i), and (j): heart, stained with hematoxyline and eosin (40x).

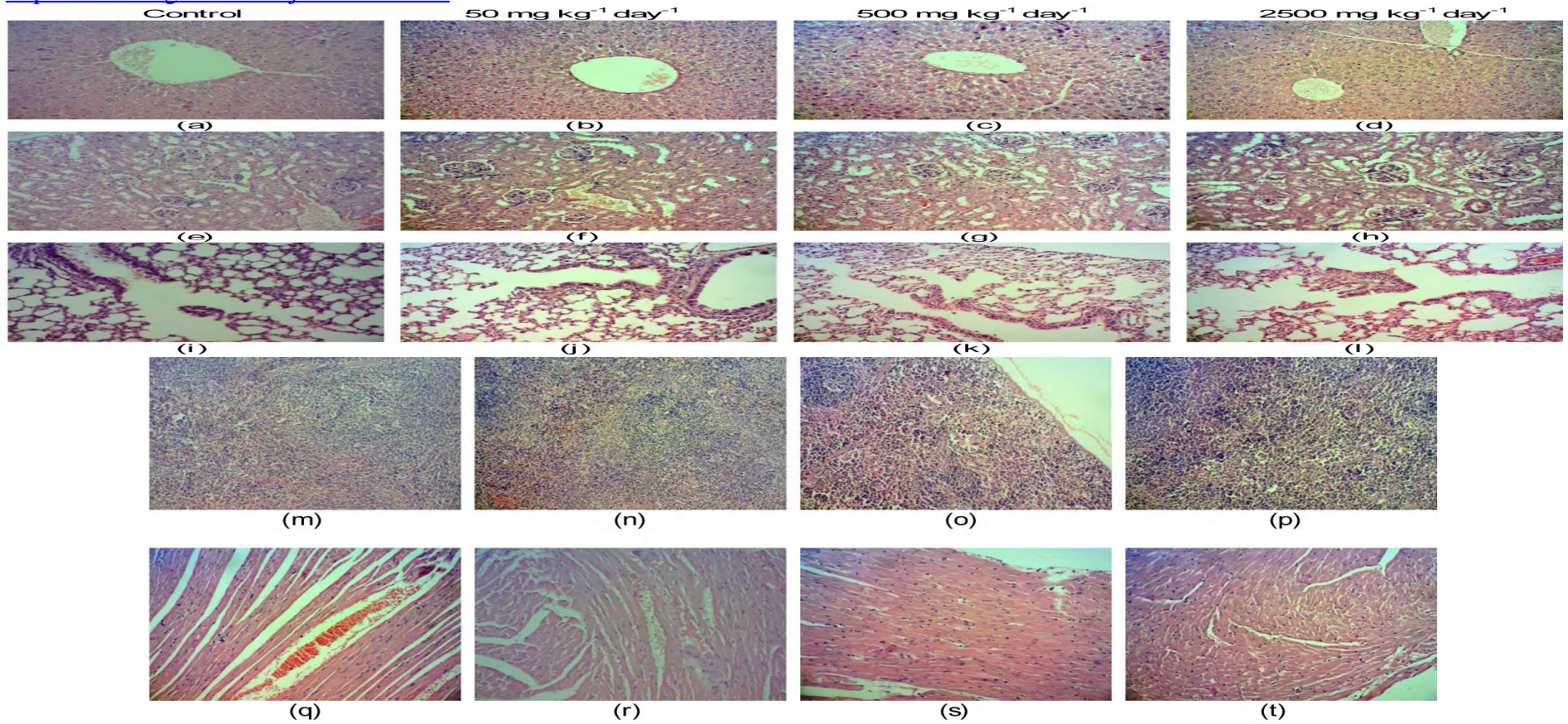


Figure 3: Photomicrographs of histopathology from representative female ICR mice in subchronic oral toxicity: (a), (b), (c), and (d): liver; (e), (f), (g), and (h): kidney; (i), (j), (k), and (l): lung; (m), (n), (o), and (p): spleen; (q), (r), (s), and (t): heart, stained with hematoxyline and eosin (40x).

Acknowledgments

This research was supported by the Fundamental Research Grant Scheme (FRGS; Reference no. 04-01-14-1445FR) awarded by the Ministry of Higher Education (MOHE), Malaysia and the internal grant, Putra Research Grant (Reference no. GP-IPM/2014/943 6200) awarded by the Universiti Putra Malaysia, Malaysia. The authors thanked the Faculty of Medicine and Health Sciences, Universiti Putra Malaysia, Malaysia for providing the facilities to carry out this research.

References

1. Agrawal, A.D. (2011). Pharmacological Activities of Flavonoids: A Review. *Int. J. Pharm. Sci. Nanotechnol.* 4(2): 1394-1398.
2. Ai, G., Liu, Q., Hua, W., Huang, Z. and Wang D. (2013). Evaluation of the total flavonoids extracted from flowers of *Abelmoschus manihot* (L.) Medic: *In vitro* and *in vivo* studies. *J. Ethnopharmacol.* 146(3): 794 -802.
3. Akachi, T., Shiina, Y., Ohishi, Y., Kawaguchi, T., Kawagishi, H., Morita, T., Mori, M. and Sugiyama, K. (2010). Hepatoprotective effects of flavonoids from shekwasha (*Citrus depressa*) against D-galactosamine-induced liver injury in rats. *J. Nutr. Sci. Vitaminol.* 56(1): 60-67.
4. Auwal, S.M., Atiku, M.K., Wudil, A.M. and Sule, M.S. (2012). Phytochemical composition and acute toxicity evaluation of aqueous root bark extract of *Securidaca longipedunculata* (Linn). *Bayero J. Pure Appl. Sci.* 5(2): 67-72.
5. Aziagba, B.O., Okeke, C.U., Ufele, A.N., Mogbo, T.C., Muako, R.O. and Ezeabara, C.A. (2013). Comparism of three phytochemical constituents of the leaf extracts of three varieties of *Capsicum Annum* in Awka, Anambra state, Nigeria in relation to their medicinal value. *Res. J. Anim. Vet. Fishery Sci.* 1(9): 20-22.
6. Bahar, E., Ara, J., Hossain, M., Nath, B. and Runi, N. (2013). Cytotoxic (*In-vitro*) effect of methanol and petroleum ether extracts of the *Aerva lanata*. *J. Pharmacogn. Phytochem.* 2(1): 92-100.
7. Bhardwaj, S. and Gupta, D. (2012). Study of acute, subacute and chronic toxicity test. *Int. J. Adv. Res. Pharm. Bio. Sci.* 2(2): 103-129.
8. Chandra, P., Sachan, N., Kishore, K. and Ghosh, A.K. (2012). Acute, sub-chronic oral toxicity studies and evaluation of antiulcer activity of Sooktyn in experimental animals. *J. Adv. Pharm. Technol. Res.* 3(2):177-123.
9. Chaudhary, M. and Krishnaraju, V. (2012). Acute toxicity studies of fixed dose combination of Ceftriaxone+Sulbactam+Ethylenediaminetetraacetic acid in *Swiss Albino* mice and *Sprague dawley* rats. *Int. J. Pharm. Bio. Sci.* 3(1): 110-122.
10. Chavalittumrong, P., Attawish, A., Rugsamon, P. and Chuntapet, P. (1995). Toxicological study of *Clinacanthus nutans* (Burm.f.) Lindau. *Bull. Dep. Med. Serv.* 37(4): 323-338.
11. Cheikhoussef, A., Shapi, M., Matengu, K. and Ashekele, H.M. (2011). Ethnobotanical study of indigenous knowledge on medicinal plant use by traditional healers in Oshikoto region, Namibia. *J. Ethnobiol. Ethnomed.* 7(10): 2-11.
12. Czaplínska, M., Czepas, J. and Gwoździński, K. (2012). Structure, antioxidative and anticancer properties of flavonoids. *Postepy Biochem.* 58(3): 235-244.
13. Dey, Y.N., Ota, S., Srikanth, N., Jamal, M. and Wanjari, M. (2012). A phytopharmacological review on an important medicinal plant - *Amorphophallus paeoniifolius*. *AYU. Int. J. Res. Ayurveda.* 33(1): 27-32.
14. Ekeanyanwu, R.C. and Njoku, O.U. (2014). Acute and subacute oral toxicity study on the flavonoid rich fraction of *Monodora tenuifolia* seed in albino rats. *Asian Pac. J. Trop. Biomed.* 4(3): 194-202.
15. Evan, G.O. (2010). *Animal clinical chemistry: A Practical Handbook for Toxicologists and Biomedical Researchers*. Boca Raton, FL : CRC Press: Taylor & Francis.
16. Gad, M.M.E., Mohammad, Y.S. and Mohammad, T.G.M. (2013). Acute and repeated-doses (28 Days) toxicity of Thymol formulation in male albino rats. *Aust. J. Basic. Appl. Sci.* 7(10): 594-601.
17. Galvez-Llompart, M., Zanni, R. and Garcia-Domenech, R. (2011). Modeling natural anti-inflammatory compounds by molecular topology. *Int. J. Mol. Sci.* 12(12): 9481-9503.
18. Gauniyal, P. and Teotia, U.V.S. (2014). Phytochemical screening and antimicrobial activity of some medicinal plants against oral flora. *Asian Pac. J. Health Sci* 1(3): 255-263.
19. Hor, S.Y., Ahmad, M., Farsi, E., Yam, M.F., Hashim, A.K., Lim, C.P., Sadikun, A. and Asmawi, M.Z. (2012). Safety assessment of methanol extract of red dragon fruit (*Hylocereus polyrhizus*): Acute and subchronic toxicity studies. *Regul. Toxicol. Pharm.* 63(1): 106-114.
20. Hor, S.Y., Ahmad, M., Farsi, E., Lim, C.P., Asmawi, M.Z. and Yam, M.F. (2011). Acute and subchronic oral toxicity of *Corioliolus versicolor* standardized water extract in Sprague Dawley rats. *J. Ethnopharmacol.* 137(3): 1067-1076.
21. Jegadeeswari, P., Nishanthini, A., Muthukumarasamy, S. and Mohan, V.R. (2012). GC-MS analysis of bioactive components of *Aristolochia krysagathra* (Aristolochiaceae). *J. Curr. Chem. Pharm. Sci.* 2(4): 226-232.
22. Jothy, S.L., Zakaria, Z., Chen, Y., Lau, Y.L., Latha, L.Y. and Sasidharan, S. (2011). Acute oral toxicity of methanolic seed extract of *Cassia fistula* in mice. *Molecules* 16(6): 5268-5282.
23. Kalaivani, T., Kanchana, G. and Rubalakshmi. (2013). Preliminary phytochemical screening of leaf extract of *Ziziphus Glabrata* B. Heyne Ex Roth. *Int. Res. J. App. Sci.* 3(5): 61-64.
24. Kalpana, R., Bulusu, S. and Kumar, A. (2012). Phytochemical and anticytotoxic activity of *Coscinium Fenestratum*. *Helix* 3: 353-356.

25. Khera, N., Thakur, Y. and Bhatia, A. (2012). Diversity in antimicrobial activity of some medicinal plants of high altitude area: *Achyranthes aspera*, *Thalictrum foliolosum*, *Valeriana wallichii*, *Hedychium spicatum*, *Woodfordia fruticosa*, *Acorus calamu*, *Eupatorium cannabinum*. Asian. J. Plant. Sci. Res. 2(5): 638-642.
26. Kiran, B., Baruah, R., Ojha, R., Lalitha, V. and Raveesha, K.A. (2011). Antibacterial and antioxidant activity of *Coffea bengalensis* Roxb. Ex Schult. Fruit against human bacteria. Res. Pharma. Biol. Chem. Sci. 2(3): 856-865.
27. Kulkarni, Y.A. and Veeranjaneyulu, A. (2012). Toxicological evaluation of the methanol extract of *Gmelina arborea* Roxb. bark in mice and rats. Toxicol. Int. 19(2): 125-131.
28. Kunsorn, P., Ruangrunsi, N., Lipipun, V., Khanboon, A. and Rungsahirunrat, K. (2013). The identities and anti-herpes simplex virus activity of *Clinacanthus nutans* and *Clinacanthus siamensis*. Asian. Pac. J. Trop. Biomed. 3(4): 284-290.
29. Lacaille-Dubois, M.A. and Wagner, H. (1996). A review of the biological and pharmacological activities of saponins. Phytomedicine 2(4): 363-386.
30. Loomis, T.A. and Hayes, A.W. (1996). Loomis's Essentials of Toxicology. 4th Ed. San Diego, CA: Academic Press.
31. Mamat, S.S., Kamarolzaman, M.F., Yahya, F., Mohmood, N.D., Shahril, M.S., Jakius, K.F., Mohtarrudin, N., Ching, S.M., Susanti, D., Taher, M. and Zakaria, Z.A. (2013). Methanol extract of *Melastoma malabathricum* leaves exerted antioxidant and liver protective activity in rats. BMC Complement. Altern. Med. 13: 326.
32. Mandegary, A., Pournamdari, M., Shariffar, F., Pournourmohammadi, S., Fardiar, S. and Shooli, S. (2012). Alkaloid and flavonoid rich fractions of fenugreek seeds (*Trigonella foenum graecum* L.) with antinociceptive and anti-inflammatory effects. Food. Chem. Toxicol. 50(7): 2503-2507.
33. Mithraja, M.J., Antonisamy, J.M., Mahesh, M., Paul, Z.M. and Jeeva, S. (2012). Chemical diversity analysis on some selected medicinally important pteridophytes of Western Ghats, India. Asian Pac. J. Trop. Biomed. 2(1): S34-S39.
34. Maobe, M.A.G., Gatebe, E., Gitu, L. and Rotich, H. (2013). Preliminary phytochemical screening of eight selected medicinal herbs used for treatment diabetes, malaria and pneumonie in Kisii region, Southwest Kenya. Eur. J. App. Sci. 5(1): 01-06.
35. National Research Council (NRC). (2006). Toxicity Testing for assessment of environmental agents: interim report. USA: National Academics Press.
36. Negi, J.S., Negi, P.S., Pant, G.J., Rawat, M.S.M. and Negi, S.K. (2013). Naturally occurring saponins: Chemistry and biology. J. Poisonous Med. Plant Res. 1(1): 6-11.
37. P'ng, X.W., Akowuah, G.A. and Chin, J.H. (2012b). Evaluation of the sub-acute oral toxic effect of methanol extract of *Clinacanthus nutans* leaves in rats. J. Acute Disease 2(1): 29-32.
38. P'ng, X.W., Akowuah, G.A. and Chin, J.H. (2012a). Acute oral toxicity study of *Clinacanthus nutans* in mice. Int. J. Pharm. Sci. Res. 3(11): 4202-4205.
39. Pannangpetch, P., Laupattarakasem, P., Kukongviriyapan, V., Kukongviriyapan, U., Kongyingyoes, B. and Aromdee, C. (2009). Antioxidant activity and protective effect against oxidative hemolysis of *Clinacanthus nutans* (Burm.f) Lindau. Songklanakarin J. Sci. Technol. 29(1): 1-9.
40. Preethi, R., Devanathan, V.V. and Loganathan, M. (2010). Antimicrobial and antioxidant efficacy of some medicinal plants against food borne pathogens. Advan. Biol. Res. 4(2): 122-125.
41. Raihan, S.Z., Monir, M.M., Biswas, P., Biswas, S.K., Chowdhury, A., Das, J. and Das, A.C. (2012). Antinociceptive activity of *Dalbergia spinosa* Roxb. Stem Barks. J. Biol. Sci. 12(3): 202-205.
42. Rajeh, M.B., Kwan, Y.P., Zakaria, Z., Latha, L.Y., Jothy, S.L. and Sasidharan, S. (2012). Acute toxicity impacts of *Euphorbia hirta* L extract on behavior, organ body weight index and histopathology of organs of the mice and *Artemia salina*. Pharmacog. Res. 4(3): 170-177.
43. Ramaswamy, R.S., Prathuyusha, N., Saranya, R., Sumathy, H., Mohanavalli, K.T., Priya, R.J., Venkatesh, J.R., Babu, C.S., Manickavasakam, K. and Thanikachalam, S. (2012). Acute toxicity and the 28-day repeated dose study of a siddha medicine Nuna Kadugu in rats. BMC Complement. Altern. Med. 12: 190.
44. Rasekh, H.R., Nazari, P., Kamli-Nejad, M. and Hosseinzadeh, L. (2008). Acute and subchronic oral toxicity of *Galega officinalis* in rats. J. Ethnopharmacol. 166(1): 21-26.
45. Rathnasamy, S., Mohammed, K., Sulaiman, S.F. and Akinboro, A. (2013). Evaluation of cytotoxic, mutagenic and antimutagenic potential of leaf extracts of three medicinal plants using *Allium cepa* chromosome assay. Int. Curr. Pharm. J. 2(8): 131-140.
46. Rout, S.P., Choudary, K.A., Kar, D.M., Das, L. and Jain, A. (2009). Plants in traditional medicinal systems - future source of new drugs. Int. J. Pharm. Pharm. Sci. 1(1): 1-23.
47. Sakdarat, S., Shuyprom, A., Pientong, C., Ekalaksananan, T. and Thongchai, S. (2009). Bioactive constituents from the leaves of *Clinacanthus nutans* Lindau. Bioorg. Med. Chem. 17(5): 1857-1860.
48. Sangkitporn, S., Chaiwat, S., Balachandra, K., Na-Ayudhaya, T.D., Bunjob, M. and Jayavasud, C. (1995). Treatment of herpes zoster with *Clinacanthus nutans* (bi phaya yaw) extract. J. Med. Assoc. Thai. 78(11): 624-627.
49. Shim, S.Y., Aziana, I. and Khoo, B.Y. (2013). Perspective and insight on *Clinacanthus nutans* Lindau in traditional medicine. Int. J. Integr. Biol. 14(1): 7-9.
50. Singh, A., Tej, K.B. and Sharma, O.P. (2011). Clinical biochemistry of Hepatotoxicity. J. Clin. Toxicol. S4: 1-19.
51. Solomon, F.E., Sharada, A.C. and Devi, P.U. (1993). Toxic effects of crude root extract of *Plumbago rosea* (Rakta chitraka) on mice and rats. J. Ethnopharmacol. 38(1): 79-84.
52. Sriwanthana, B., Chavalittumrong, P. and Chompuk, L. (1996). Effect of *Clinacanthus nutans* on Human Cell-mediated Immune response *In Vitro*. Thai. J. Pharm. Sci. 20: 261-267.

53. Teo, S., Stirling, D., Thomas, S., Hoberman, A., Kiorpes, A. and Khetani, V.(2002). A 90-day oral gavage toxicity study of D-methylphenidate and D,L-methylphenidate in Sprague Dawley rats. *Toxicology* 179(3): 183-196.
54. The Organization of Economic Co-operation and Development (OECD). (2008a). The OECD Guideline for the Testing of Chemicals: No. 425 Acute Oral Toxicity: Up-and-Down Procedure (UDP). Paris, OECD.
55. The Organization of Economic Co-operation and Development (OECD). (2008b). The OECD Guideline for the Testing of Chemicals: No. 407 Repeated Dose 28-Day: Oral Toxicity study in Rodents. Paris, OECD.
56. Timpawat, S. and Vajrabhaya, L. (1994). Clinical evaluation of *Clinacanthus nutans* Lindau in orabase in the treatment of recurrent aphthous stomatitis. *Mahidol Dental J.* 14(1): 10-16.
57. Toker, G., Küpeli, E., Memisoğlu, M. and Yesilada, E. (2004). Flavonoids with antinociceptive and anti-inflammatory activities from the leaves of *Tilia argentea* (Silver Linden). *J. Ethnopharmacol.* 95(2-3): 393-397.
58. Tubesha, Z., Iman, M.U., Mahmud, R. and Ismail, M. (2013). Study on the potential toxicity of Thymoquinone-rich fraction nanoemulsion in sprague dawley rats. *Molecules* 18(7): 7460-7472.
59. Ukwuani, A.N., Abubakar, M.G., Hassan, S.W. and Agaie, B.M. (2012). Toxicological studies of hydromethanolic leaves extract of *Grewia crenata*. *Int J Pharma Sci Drug Res*, 4(4): 245-249.
60. Vaghasiya, Y.K., Shukla, V.J. and Chanda, S.V. (2011). Acute oral toxicity study of *Pluchea arguta* Boiss extract in mice. *J. Pharmacol. Toxicol.* 6: 113-123.
61. Verma, S. and Singh, S.P. (2008). Current and future status of herbal medicines. *Vet. World.* 1(11): 347-350.
62. Wanikiat, P., Panthong, A., Sujayanon, P., Yoosook, C., Rossi, A.G. and Reutrakul, V. (2008). The anti-inflammatory effects and the inhibition of neutrophil responsiveness by *Barleria lupulina* and *Clinacanthus nutans* extracts. *J. Ethnopharmacol.* 116(2): 234-244.
63. Yadav, RNS. and Agarwala, M. (2011). Phytochemical analysis of some medicinal plants. *J. Phytol.* 3(12): 10-14.
64. Yahya, F., Mamat, S.S., Kamarolzaman, M.F.F., Seyedan, A.A., Jakius, K.F., Mahmud, N.D., Shahril, M.S., Suhaili, Z., Mohtarrudin, N., Susanti, D., Somchit, M.N., Teh, L.K., Salleh, M.Z. and Zakaria, Z.A. (2013). Hepatoprotective activity of methanolic extract of *Bauhinia purpurea* leaves against paracetamol-induced hepatic damage in Rats. *Evid. Based. Complement. Altern. Med.* 2013: 636580.
65. Yang, H.S., Peng, T.W., Madhavan, P., Shukkoor, M.S.A. and Akowuah, G.A. (2013). Phytochemical analysis and antibacterial activity of methanolic extract of *Clinacanthus nutans* Leaf. *Int. J. Drug. Dev. Res.* 5(3): 369-355.
66. Yong, K.Y., Tan, J.J., Teh, S.S., Mah, S.H., Ee, G.C., Chiong, H.S. and Ahmad, Z. (2013). *Clinacanthus nutans* extracts are antioxidant with antiproliferative effect on cultured human cancer cell lines. *Evid. Based. Complement. Altern. Med.* 2013: 462751.
67. Zakaria, Z.A., Mohamed, A.M., Jamil, N.S., Rofiee, M.S., Hussain, M.K., Sulaiman, M.R., Teh L.K. and Salleh, M.Z. (2011a). *In vitro* antiproliferative and antioxidant activities of the extracts of *Muntingia calabura* leaves. *Am. J. Chin. Med.* 39(1): 183-200.
68. Zakaria, Z.A., Rofiee, M.S., Mohamed, A.M., Teh L.K. and Salleh, M.Z. (2011b). *In vitro* antiproliferative and antioxidant activities and total phenolic contents of the extracts of *Melastoma malabathricum* leaves. *J. Acupunct. Meridian Stud.* 4(4): 248-256.