

ROTECTIVE EFFECT OF FENGLIAO-CHANGWEIKANG EXTRACTS, A TRADITIONAL CHINESE HERBAL MEDICINE FORMULA, ON MUCOSA IN RAT WITH CHRONIC GASTRITIS

Shou-zhong Ren<sup>1</sup>, Jian-sheng Guo<sup>2\*</sup>, Lin Sheng<sup>1</sup>, Chen Jun<sup>3</sup>, Shui-ping Dai<sup>1</sup>, Zhi-jian Ma<sup>4\*</sup>

<sup>1</sup>School of Pharmacy, <sup>4</sup>Department of Human Anatomy, Hainan Medical University, Haikou, 571199, China. <sup>2</sup>Hunan Medical University, Key Laboratory of Traditional Chinese Medicine Modernization, Changsha, 410208, China. <sup>3</sup>Department of pharmacy, Hainan Provincial People's Hospital, Hainan Haikou 571017

E-mail: [rsz1029@126.com](mailto:rsz1029@126.com)

## Abstract

**Background:** Fengliao-Changwei-Kang(FCK), the Chinese patent drug, is a famous traditional Chinese herbal medicine formula. It has a significant effect on the clinic treatment of gastrointestinal diseases including gastritis, enteritis and diarrhea for many years. However, there is few research on the protective effects of FCK on the gastric mucosa of chronic gastritis (CG) model rat.

**Objective:** The present study aimed to explore the effects of FCK extract on mucosa in rats with Chronic Gastritis.

**Materials and Methods:** 50 SD mice were randomly divided into 5 groups with 10 in each group (five per sex). The groups are respectively control group, model group, low, middle and high FCK extracts (FCK I, II and III) group. The CG rat model was induced by synthetic methods. FCK I, II and III group were administrated with FCK extracts at 2.16g• kg, 4.32g• kg, 8.94g• kg once per day for 21 consecutive days, and the control group and model group were administrated the same volume of distilled water at 10mL/kg once per day. 16 hours after the last administration, the rats were anesthetized and their blood and stomach were drawn from vena cava and abdominal cavity. The serum levels of EGF was measured by enzyme linked immunosorbent assay(ELISA) method, the expression of growth factor receptor (EGFR) in gastric mucosa was detected by immunohistochemical method, and the mRNA expressions of NF-κB p65 was detected in-situ hybridization.

**Results:** The inflammation grades and the expressions of NF-κB p65 mRNA in gastric mucosa of the model group were markedly higher than those of the control group (P<0.05). The inflammation grades of gastric mucosa and the expressions of NF-κB p65 mRNA in gastric mucosa the FCK extract group are significantly lower than those of the model group, and the FCK extract group at 8.64g/kg could greatly increase the serum levels of EGF and the expressions of EGFR in gastric mucosa. High EGF level was found in FCK extract group at 4.32g/kg, but low in FCK extract groups at 2.16g/kg. There were no marked differences among the rats from control group, model group and FCK extract group on ratio of LI/L2 (P>0.05).

**Conclusions:** FCK extract could alleviate mucosal inflammation by down regulating the expressions of NF-κB p65 mRNA and promote tissue repair by up regulating EGFR expression in gastric mucosa cell.

**Keywords:** chronic gastritis; fengliao-changwei-kang extract; epidermal growth factor receptor; nuclear factor kappa B.

## Introduction

Chronic gastritis (CG) is a disease in gastric mucosa of non-specific chronic inflammatory lesions caused by many reasons. The basic pathological changes are gastric mucosal epithelial degeneration and inflammatory cell infiltration. The lesions are almost confined to the superficial mucosa, but sometimes also involved the whole layer (Ye and Lu. 2005). If the situation is allowed to continue, atrophic gastritis will appear and about 8% will become cancer. Studies have shown that the expression of TNF-α, IL-1 and other cytokines in the gastric tissues of patients of chronic gastritis was significantly higher than that of control people. The inflammatory cytokines can induce neutrophil accumulation in gastric mucosa and cause inflammatory reaction (Wang et al., 2007). The nuclear factor-κB is, in the process of inflammation, a key transcription factor regulating the gene expression of many inflammatory cytokines. It has become, consequently, an interesting targets for anti-inflammation drug therapy.

Some traditional Chinese herbs and formula, such as FCK, are documented for the treatment of chronic gastritis. The formula mainly consists of two plant materials: *Daphniphyllum calycinum* and *Polygonum hydropiper* Linn (Liu et al., 2010). FCK is used clinically to treat

acute and chronic gastrointestinal disease such as chronic gastritis, enteritis, which has obvious effect (Wang, 2012). A few papers reported its pharmacology activities including reducing the acidity of gastric juice, relaxation of intestinal smooth muscle and inhibition of gastric emptying. The previous studies of the author indicated that the 70% ethanol extract of this formula exhibited significant anti-inflammatory activity. In addition, further studies have found that the 70% ethanol extract could inhibit intestinal smooth muscle contraction (Zeng et al., 2008). However, there are no scientific reports about the protective effects of FCK extracts on the gastric mucosa of chronic gastritis rats. This paper is designed to determine the serum levels of EGF and the expression of EGFR and NF- $\kappa$ B p65mRNA in gastric mucosa in the purpose of exploring the effects of FCK extracts on the gastric mucosa.

## Experimental methods

### Reagents

Anhydrous ethanol was purchased from Hunan Hui Hong Reagent Co. Ltd (Changsha, China). 28% Ammonia was obtained from Hunan Chemical Industry Research Institute (batch No.20100317; Zhuzhou, China). Sodium deoxycholate was products of Sigma company((St Louis, USA). rat ECG agent box, mouse polyclonal antibody against EGFR and NF- $\kappa$ B/p65mRNA, situ hybridization Kit and SABC kit were purchased from Wuhan booster company (Wuhan, China).

### Animals

50 SD rats(180-220g), half male and half female, purchased from Slack JingDa Laboratory Animal Co. Ltd, Changsha, China, [Certificate No: SCXK (Xiang) 2009-0001], Rats were fed under the condition of controlled temperature ( $21\pm 2^{\circ}\text{C}$ ), relative humidity (about  $60\%\pm 10\%$ ), 12-hour light/dark cycle and automatic ventilation 8-15 times every hour. All experimental were performed in accordance with the Guidance Suggestions for the Care and Use of Laboratory Animal, issued by the Ministry of Science and Technology of China, 2006)

### Plant material

The stem and leaves of *Daphniphyllum calycinum* and *Polygonum hydropiper* linn were collected from the Hainan province of China and its identity was confirmed by our plant taxonomy research group. voucher specimens were deposited in the School of Pharmaceutical Science, Hainan Medical University.

### Preparation of FCK extracts

For the preparation of 70% ethanol extract, according to the requirement of the prescription, the air-dried stem and leaves of FCK were extracted with water (1h,  $98^{\circ}\text{C}$ ) after grinding into powder. The solvent was removed under reduced pressure to afford the water decoction of FCK, the same extraction procedures were repeated once, the obtained decoction was combined and condensed. Then the solution was subjected to HP-20 column chromatography using  $\text{H}_2\text{O}$  and mixture solvent ( $\text{H}_2\text{O}/\text{EtOH}=3:7$ ) successively as the eluents. The obtained  $\text{H}_2\text{O}$  elution was discarded. The mixture solvent eluent was collected and concentrated to a concentration of 1g/ml under reduced pressure, which was then freeze dried and get extract of FCK, and has been previously assigned as the active fraction of the FCK.

The ethanol extract prepared in de-ionized water and distilled water was added at the necessary concentrations for future use, and samples were shaken to ensure an equal distribution of the components prior to use.

### Model

The chronic gastritis model is similar to the previously described method (Chen et al.,2002). Rats were orally administrated with 60% alcohol 1 times every Tuesday and Friday on an empty stomach, 2mL each time; 20mmol/L sodium deoxycholate orally, 1 time each day, 2mL each time; 0.05% ammonia in the 1st-6th week, 0.1% ammonia free drinking in the 7th-12th week; irregular diet: 2d enough feeding, 1d fasting.

The whole procedure lasted 12 weeks (in the process of modeling, 2 rats were dead due to incorrect administration).

### Group and administration

The 50 mice were randomly divided into 5 groups with 10 in each group (five per sex), respectively, control group, model group, FCK extracts groups (FCK The adult clinical dosage of FCK is 24g crude drug/d. According to the conversion method of body surface area, the dosage of the rat of 200 grams is equivalent to 0.018 times of adult's. That is, the equivalent dose is 2.16g/kg. The 1, 2, 4 times of the equivalent doses are used respectively as low, medium and high doses of rats). FCK extracts low, middle and high (FCK I, II and III) group were orally administrated with FCK extracts at 2.16g• kg, 4.32g• kg, 8.94g• kg once daily for 21 consecutive days. Control group and model group were administrated the same volume of distilled water at 10mL/kg once daily.

### EGF Content in Serum.

16h after the last administration, rats were anesthetized by 4% sodium pentobarbital and drawn blood from vena cava. The blood was placed at room temperature for 30min, centrifugal for 10min at the rate of 1500r/min<sup>-1</sup> to separate the serum. The content of EGF was measured according to ELISA kit.

### Pathological examination of Gastric Mucosa.

All the rats were euthanized after blood sampling. The stomach was removed from abdominal cavity, washed with distilled water, fixed with 10% of formaldehyde, dewaxed with xylene, stained with HE, and then observed under light microscope. The mucosal inflammation score was detected by semi quantitative method.

At the place that is 250±50µm from the pylorus ring, the thickness of mucosa layer (L2) and muscle layer(L1) of gastric antrum was respectively measured with micrometer, and the ratio of L1 and L2 was calculated.

### EGFR and NF-κB p65 mRNA expression in Gastric Mucosa.

Analysis methods of EGFR refer to operating instruction. 5 vision were randomly selected and taken photos under the 200 times optical microscope, each picture was scanned on the computer with HPIAS-1000 pathological image analysis system. The ratio of average optical density and the positive cells ratio (that is, the area of positive cells / total area of statistical field) were took as the determination index.

The tissue sections were treated with 3% H<sub>2</sub>O<sub>2</sub> at room temperature for 10 minutes and washed twice in distilled water. Adding proteinase in sections at 37°C for 20 minutes. Sections were then washed triple with 0.5mol/L PBS, five minutes each time. The slides were add 20uL pre-hybridization liquid at 37°C for 4 hours, then the excess liquid was absorbed, each slides were added 20ul hybridization liquid and covered with special slice overnight at 4°C. then, The slides were washed twice in 2%SSC for five minutes each, once in 0.5%SSC and in 0.2%SSC for fifteen minutes, respectively. The slides were then added antibody visualisation of digoxigenin. The slides were added pre-biotinylated anti-digoxigenin antibody SABC and biotinylated peroxidase, successively. then Incubate at 37°C for twenty minute and washed three times in 0.5mol/LPBS for five minutes each. The slides were stained by DAB and hematoxylin, then washed in water. finally the slides were covered with neutral gum, after took a photo, optical density value and rate of positive area were detected by HPIAS-1000 pathological image- text analytical system .

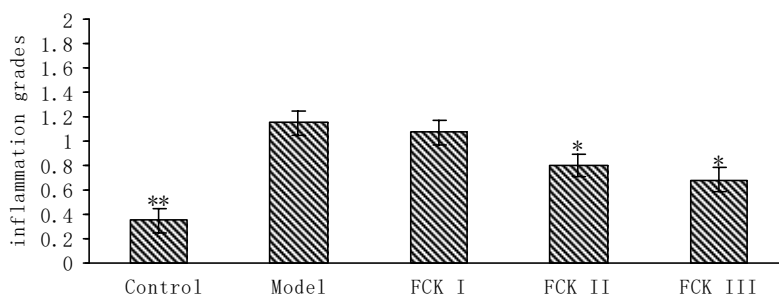
### Statistical Analysis

All data were expressed as the mean±standard deviation (SD). Statistical analysis was conducted via ANOVA, followed by a two-tailed Student's t-test using SPSS Proprietary Software Release 17.0. Comparisons between groups were carried out with analysis of non-paired Student's t-test. Data with *p* values<0.05 were considered to be statistically significant.

## Results

### Inflammation grades of gastric mucosa

As shown in Figure 1, in the model group, the inflammation grades of gastric mucosa were obviously high. In FCK II and III group, the inflammation scores of gastric mucosa were obviously low. There were occasionally lymphocytes on the mucosal surface, but no change in the FCK I group.

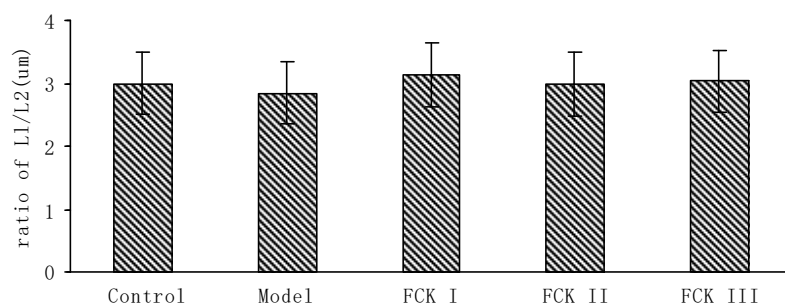


**Figure 1:** Inflammation grades of gastric mucosa.

Values are expressed as mean  $\pm$  SD (n =10 ).Control: control group; Model: model group; FCK I: 2.16g/kg body weight FCK extracts treated group; FCK II: 4.32g/kg body weight FCK extracts treated group; FCK III: 8.64g/kg body weight FCK extractstreated group. \*p < 0:05, \*\*p < 0:01compared with the model group.

### The ratio of L1/L2.

The effects of FCK extracts on ratio of L1/L2 were shown in Figure 2. In control group, the gastric mucosal glands arranged closely and regularly. However, the mucosal glands of gastric antrum in the model group arranged in disorder and irregularly, but glandular layer were not obviously become thinning or thickening (P>0.05). The gastric antrum mucosa glands were arranged more orderly in the FCK extracts groups of three doses. The L1/ L2 ratio had no significant difference in all experimental groups (P>0.05).

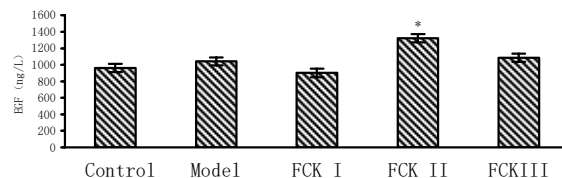


**Figure 2:** Effect of FCK extracts on ratio of L1/L2 in CG rats.

Values are expressed as mean  $\pm$  SD (n =10 ).Control: control group; Model: model group; FCK I: 2.16g/kg body weight FCK extracts treated group; FCK II: 4.32g/kg body weight FCK extracts treated group; FCK III: 8.64g/kg body weight FCK extracts treated group.

### Content of EGF in serum

As shown in Figure 3, The serum levels of EGF in model group was increased as compared with the control group, but no significant differences (P>0.05). Compared with model group, EGF level was significantly decreased in FCK II and FCK I group (P<0.05), but no statistical significance. There was no change in FCK I group.

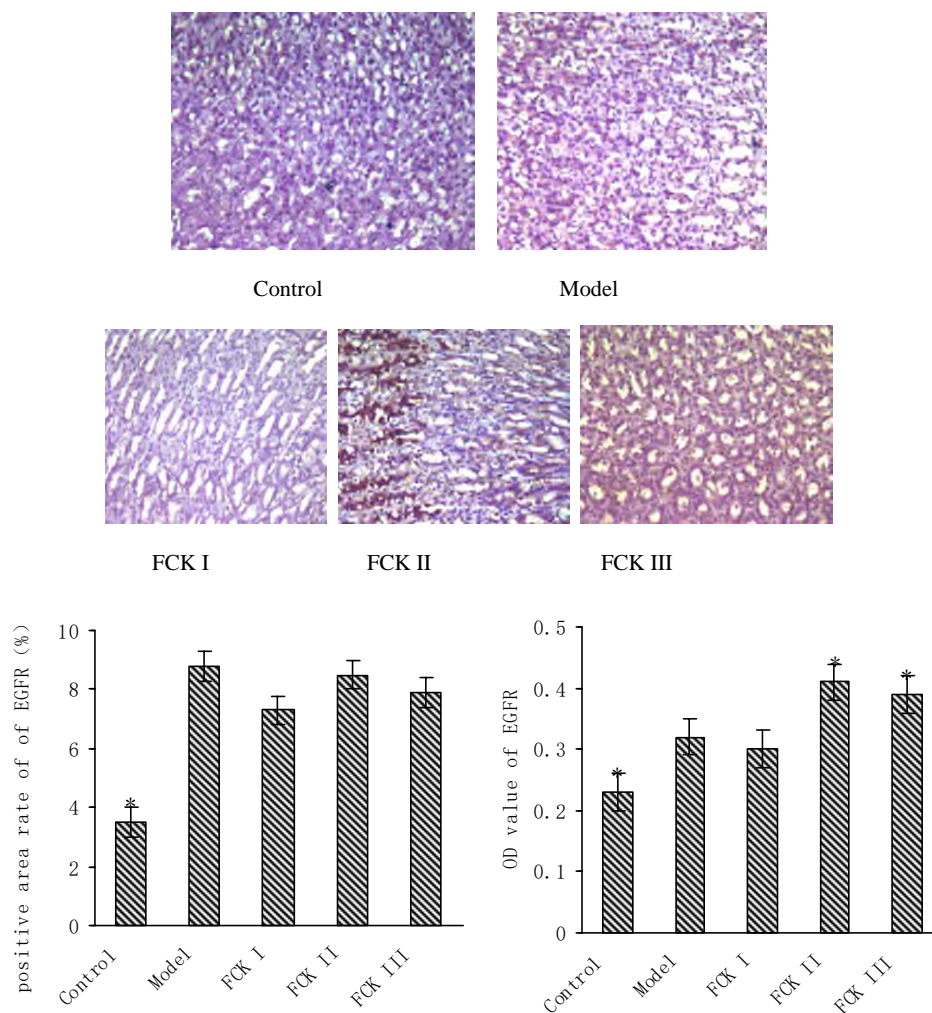


**Figure 3:** Effect of FCK extracts on EGF in CG rats.

Values are expressed as mean ± SD (n =10 ).Control: control group; Model: model group; FCK I: 2.16g/kg body weight FCK extracts treated group; FCK II: 4.32g/kg body weight FCK extracts treated group; FCK III: 8.64g/kg body weight FCK extracts treated group. \*p < 0:05, compared with the model group.

**Immunohistochemical analysis of EGFR expression.**

Figure 4 shows the effect of FCK extracts on EGFR expression in gastric mucosa cell. The positive expression of EGFR was showed as brown yellow granules, and mainly distributed in the cytoplasm and cell membrane. Compared with control group, EGFR expression significantly increased in the rats of the model group, and optical density value and the number of positive cells of EGFR were significantly increased(P<0.05). The optical density value of EGFR in gastric mucosa raised in FCK II and III group, but no change in FCK I group.

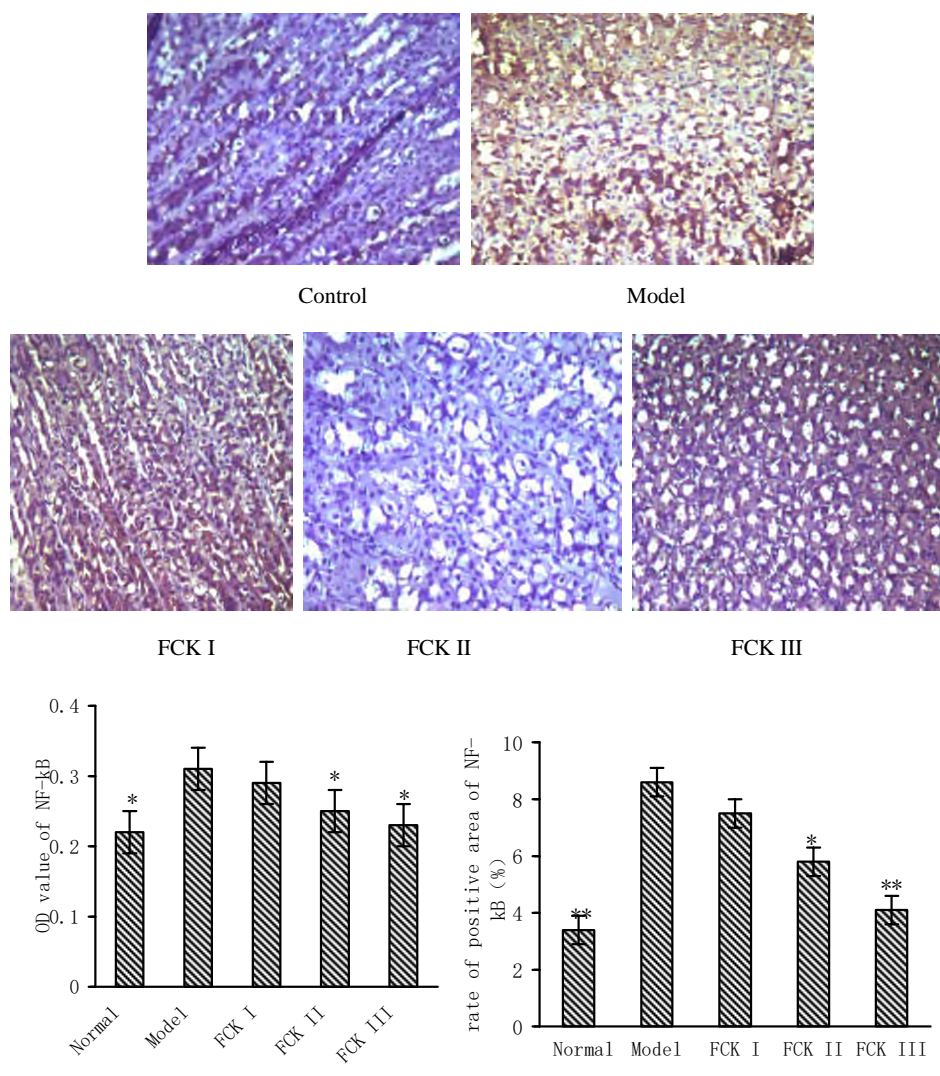


**Figure 4:** EGFR expression in gastric mucosa cell.

Values are expressed as mean ± SD (n =10 ).Control: control group; Model: model group; FCK I: 2.16g/kg body weight FCK extracts treated group; FCK II: 4.32g/kg body weight FCK extracts treated group; FCK III: 8.64g/kg body weight FCK extracts treatedgroup. \*p <0:05 compared with the model group.

**Analysis of in situ hybridization of NF-κB mRNA expression.**

We could read from the Figure 5 that the positive expression of NF-κB mRNA p65 was mainly present at cytoplasm, showed as brown yellow granules. In control groups, the expression of NF-κB mRNA p65 of gastric mucosa was rare. However, the expression in the model group was evidently increased and unevenly distributed, and the optical density value and the number of positive cells obviously raised as compared to the control group. The NF- κ B p65mRNA p65 expression in FCK II and III group decreased obviously, and the value of optical density and the number of positive cells were significantly lower than those in the model group(P<0.01 or 0.05), but the changes of FCK III group had no difference.



**Figure 5:** NF-κB mRNA expression in gastric mucosa cell.

Values are expressed as mean ± SD (n =10 ).Control: control group; Model: model group; FCK I: 2.16g/kg body weight FCK extracts treated group; FCK II: 4.32g/kg FCK ody weight FCK extracts treated group; FCK III: 8.64g/kg FCK ody weight FCK extracts treated group.\*p < 0:05,\*\*p < 0:01 compared with the model group.

## Discussion

This study uses the integrated method of giving 60% ethanol, 20mmol • L<sup>-1</sup> sodium deoxycholate, 0.01% ammonia water and irregular diet. After 12 weeks modeling, pathologic examination has shown that, the inflammation grades of gastric mucosa of the model group were obvious high, and there was a large number of inflammatory cell infiltration and obvious gastric mucosal injury (Ren et al., 2011), while the inflammation scores were obvious low in the control group. The gland arranged irregularly, but there were no significant thinning or thickening. There was no change ( $P>0.05$ ) of the ratio of L1 and L2 as compared with the control group, which were different from the atrophic gastritis and chronic gastritis cancer stage (Si et al., 2001). After oral administration of FCK extracts for 21 days, gastric epithelial cells arranged more orderly, the lymphocyte infiltration was decreased significantly (except FCK I group), the gastric antrum glands neatly arranged, and the ratio of L1/ L2 was no difference with the model group ( $P>0.05$ ). The experimental results suggested that the FCK extracts could restrain the infiltration of inflammatory cells, alleviate mucosal inflammatory reaction and reduce mucosa injury, which indicates that this extracts could prevent the chronic gastritis.

EGF is secreted by submandibular gland, salivary gland, pancreas and duodenum (Kameda et al., 1992; Tepperman et al., 1990). It can restrain the secretion of gastric acid, protect the gastric mucosa and promote gastric epithelial repair and regeneration (Savage et al., 1983; Jansen et al., 1997). After the administration of FCK extracts, the author observed the effect of FCK extracts on the levels of EGF in the serum of rats, and found that the FCK II extracts could obviously increase the EGF levels in the serum, which indicates that the effect of mucosal protection of the FCK extracts may be have a relevance with EGF increase, which could contribute to mucosa repair by binding to its receptor.

EGFR is the products of C-erb-1 gene expression (Yarden et al., 2001). Combined with its ligand (EGF), it may activate the tyrosine kinase and regulate division, differentiation and proliferation of cells. The appropriate level of EGFR is conducive to the gastric mucosal repair and regeneration (Mendelsohn, 2002). Studies have found that EGFR expression was the lowest in non atrophic gastritis tissues (Mo et al., 2008). Therefore, EGFR was thought to have close relationship with stimulating cell proliferation and promoting mucosal repair (Kim et al., 2008; Moutinho et al., 2008). In recent years, therapy of EGFR as a target has a good curative effect on the prevention and treatment of the injury of gastric mucosa (Konturek PC et al., 2001; Zhang et al., 2014), but sustained overexpression of it can increased the risk of chronic atrophic gastritis development and carcinogenesis (Patel et al., 2009; Mitsui, et al., 2007; Kosaka, et al., 2006).

Therefore, the reasonable control of its expression is significant. It's best to have the effect of promoting mucosal repair without excessive proliferation. The experimental results has shown that the EGFR expression in gastric mucosa of the control rats is less, while increased in the model group, and the optical density value and positive area ratio of EGFR were increased, which may be a response to the reactivity increase of EGFR expression after chronic inflammation stimulated and destroyed the gastric mucosa. The results is consistent with those reported in the literature, but the long-term inflammatory stimulation can make mucosal hyperplasia out of control and then carcinogenesis. Therefore, the detection of its changes is helpful to the judgement of the degree of gastric mucosal lesions and the prognosis of the disease.

The experimental results show that, after the treatment with FCK extracts, the optical density value and positive area percentage of EGFR in gastric mucosa increased significantly in FCK II group, while other groups had no significant changes, which indicates that the FCK extracts may raise the expression of EGFR and promote mucosal repair. However, as for, the author needs to take a deeper research on its mechanism of action in the future. The study also found that the changes of EGF and EGFR remained consistent. After the treatment with FCK extracts, in II and III group, EGF and EGFR increased at the same time, and FCK II group increased more significantly ( $P<0.05$ ), but the FCK I group had no significant change. The data showed that, when combined with ligand (EGF), EGFR may regulate differentiation, proliferation and repair of gastric mucosa, which is consistent with literature reports (Chen et al., 2013).

The NF- $\kappa$ B is an important kind of transcription factor that exist in cell in the course of inflammation and immunoreaction (Zhen et al., 2001). Altavilla discovered that the NF- $\kappa$ B was a transcription factor of quick response, which worked by expressing inflammatory mediator, adhesion molecules, enzyme and so on in inflammatory process (Altavilla et al., 2001). There are functional combined point of NF- $\kappa$ B in many gene promoters and enhancers, which may promote and adjust transcription and regulation of many cell factor and inflammatory mediator related to inflammation. NF- $\kappa$ B is usually combined with inhibition protein I $\kappa$ B and stored in the cytoplasm in non active state. Some intracellular and extracellular stimuli may activate the IKK enzyme, which makes I $\kappa$ B to phosphorylate and degradant. After NF- $\kappa$ B p65 has been released and turned into cell, it can cause release of inflammatory factors (IL-1, IL-2, TNF- $\alpha$ ) and inflammatory response by regulating transcription and expression of genes related to inflammation. In the same way, inflammatory factors can also make further NF- $\kappa$ B activation

and that arouse cascade response. As a result, the inflammation will continue and enlarge(Yanai et al., 2008; Kin et al.,2006).So, restraining activation of NF- $\kappa$ B will be helpful in the treatment of inflammatory disease, The study showed that many traditional chinese medicine can restrain inflammatory reaction through restraining activation of NF-  $\kappa$ B (Li et al., 2007).

The experimental results show that the positive expression of NF-  $\kappa$ B p65mRNA of gastric mucosa in control rats were low, while obviously increased in model rats. After treatment of FCK, The optical density value and rate of positive area of NF-  $\kappa$ B mRNA raised obviously as compared with control rats( $P<0.01$ ), which was correspond with report from Cui-Najuan(Cui et al., 2010). NF-  $\kappa$ B expression decreased significantly in FCK extracts II and III group, The value of optical density and the positive rate of area of NF-  $\kappa$ B mRNA was lower than that in the model group( $p<0.05$ ).The study has shown FCK extracts could restrain the inflammatory cytokines (such as IL-2,TNF- $\alpha$ ) transcription and release by down-regulating the expression of NF-  $\kappa$ B p65 expression, in the purpose of reducing mucosal inflammation reaction.

## Conclusion

In summary, FCK extracts could alleviate mucosal inflammation reaction by down-regulating expression of the NF- $\kappa$ B p65 to restrain the inflammatory cytokine release and promote mucosal recovery by up-regulating expression of EGFR to regulate cell proliferation,

## Acknowledgements

This work was funded by grants from National natural science foundation (81441137),.

**Conflict of interests:** We have no conflict of interest.

## References

1. Altavilla, D., Saitta, A., Guarini, S.(2001). Oxidative stress causes nuclear factor-kappa B activation in acute hypovolemic hemorrhagic shock. *Free Radic Biol Med.* **30**: 1055-1066.
2. Chen, C., Long, Z.J., Cai, M.M.(2013). Effects of Weishuling on the Expression of Epidermal Growth Factor and Epidermal Growth Factor Receptor in Stomach Mucosa of Chronic Gastritis Rats. *China J Experi TCM Formulae.* **19**: 283-285.
3. Chen, X.Y., Zou, S.J. (2002). Pathological Changes of Gastric Mucosal in Rat Models of Combined CAG Syndrome and Disease. *J Shanghai Labo Ani Sci.* **20**: 292-295.
4. Cui, N.J., Hu, L., Lao, S.Z. (2010).Relationship between Pi-Wei Damp-Heat Syndrome with Expressions Nuclear Factor- $\kappa$ B mRNA and Heat Shock Protein 70 mRNA in Patients Chronic Gastritis. *Chinese J of integrative medicine.* **30**: 18-21.
5. Jansen, C. and Ihse, I., Axelson.(1997). Epidermal growth factor induces increased mucosal thickness of the small intestine in mouse. *Eur Surg Res.* **29**:447-454.
6. Kameda, T., Yasui, W., Tsujino, T.(1992). Tyrosine kinase activity of epidermal growth factor receptor in human gastric carcinoma. *Pathol Res Pract.* **188**:37-40.
7. Kim, M.A., Lee, H.S., Lee, H.E., Jeon, Y.K., Yang, H.K., Kim, W.H. (2008). EGFR in gastric carcinomas: prognostic significance of protein overexpression and high gene copy number. *Histopathology.***52**:738-746.
8. Kin, S.Y., Lee, Y.L., Kim, H.K., Blaser, M.J. (2006). Helicobacter pylori CagA transfection of gastritis epithelial cells induces interleukin. *Cell Microbio.* **8**: 97-100.
9. Konturek, P.C., Brzozowski, T., Duda, A., Kwiecien, S., Löber, S., Dembinski, A., Hahn, E.G., Konturek, S.J.. (2001). Epidermal growth factor and prostaglandin E 2 accelerate mucosal recovery from stress-induced gastric lesions via inhibition of apoptosis. *J Physiol Paris.* **95**:361-7.
10. Kosaka, T., Yatabe, Y., Endoh, H., Kuwano, H., Takahashi, T., Mitsudomi, T. (2006). Mutations of the epidermal growth factor receptor gene in gastrointestinal tract tumor cell lines. *Oncol Rep.* **15**:1205-1210.



11. Li, H., Xiong, L., Zhou, Q.R. (2007). The research progress on traditional Chinese medicine regulation of nuclear factor- $\kappa$ B activation. *Journal of traditional Chinese Medicine*. **35**: 54-57.
12. Liu, M.S., Liu, C., Zhang, X.P., Yuan, Z. (2010). Study on the chemical constituents of Traditional Chinese medicine compound-Changweikang. *World science and technology: Modernization of Traditional Chinese Medicine and Materia Medica*. **12**:614-616.
13. Mendelsohn, J. (2002). Targeting the epidermal growth factor receptor for cancer therapy. *J Clin Oncol*. **20**: 1S-13S.
14. Mitsui, F., Dobashi, Y., Imoto, I., Inazawa, J., Kono, K., Fujii, H., Ooi, A. (2007). Non-incident coamplification of Myc and ERBB2, and Myc and EGFR in gastric adenocarcinomas. *Modern Pathology*. **20**:622-631.
15. Mo, Y.S., Chen, Z.Y., Yan, M.X. (2008). Expression and Significance of Epidermal Growth Factor Receptor Cyclooxygenase-2 and Trefoil Factor 1 in the Carcinogenesis of Gastric Mucosa. *China J Gastroenterology*. **13**: 159-162.
16. Moutinho, C., Mateus, A.R., Milanezi, F., Carneiro, F., Seruca, R., Suriano, G. (2008). Epidermal growth factor receptor structural alterations in gastric cancer. *BMC Cancer*. **8**: 1186-1195.
17. Patel, D., Bassi, R., Hooper, A., Prewett, M., Hicklin, D.J., Kang, X. (2009). Anti-epidermal growth factor receptor monoclonal antibody cetuximab restrains EGFR/HER-2 heterodimerization and activation. *Int J Oncol*. **34**: 25-32.
18. Ren, S.Z., Ma, Z.J., Wang J.H., Zeng, G.R. (2011) Establishment of Model of Chronic Superficial Gastritis in Rat. *Chin J of Experi Traditi Medic Formulae*. **17**: 191-193.
19. Savage, CR. Jr., Hash, J.H., Cohen, S. (1973). Epidermal Growth Factor. Location of disulfide bonds. *J Biol Chem*. **48**: 7669-7672.
20. Si, J.M., Wu, J.G., Cao, Q., Xiang, Z., Jiang, L.L., Lv, W., Huang, H.D. (2001). Establishment of chronic atrophic gastritis and study of the factors inducing atrophy in a rat model. *Chi J Dig*. **21**: 75-78.
21. Tepperman, B.L., and Soper, B.D. (1990). Effect of sialoadenectomy on gastric mucosal integrity and growth in the rat. A time-course study. *Dig Dis Sci*. **18**: 35-37.
22. Wang, L.J. (2012). Efficacy and safety of Fengliao Changweikang Capsule in the treatment of acute Gastroenteritis. *Chinese Traditional Patent Medi*. **34**:7-9.
23. Wang, W.H., Li, P., Zhang, L. (2007). Correlation analysis of chronic superficial gastritis with syndrome type of TCM and gastric mucosal cytokines. *Beijing J of TCM*. **26**: 80-82.
24. Yanai, A., Maeda, S., Shibata, W., Hikiba, Y., Sakamoto, K., Nakagawa, H., Ohmae, T., Hirata, Y., Ogura, K., Muto, S., Itai, A., Omata, M. (2008). Activation of kappa B kinase and NF-kappa B is essential for Helicobacter pylori-induced, chronic gastritis in Mongolian gerbils. *Infect immun*. **76**: 781-787.
25. Yarden, Y. and Sliwkowski, M.X. (2001). Untangling the ErbB signaling network. *Nat Rev Mol Cell Bio*. **7**: 127-137.
26. Ye, R.G., Lu, Z.Y. (2005). *Internal medicine*. Version 6, People's Medic Publishing House, Beijing. 380.
27. Zeng, X.Z., Yang, W.L., Zhang, J.Q. (2008). Study on anti-acute gastroenteritis effect of Fengliao extract. *China J of hospital pharmacy*. **28**:87-89.
28. Zhang, H, Guo, H., Zhang, Y.C., Liu, M., Ai, K., Su, Y.M., Li, M.H., Li, T.L. (2014). Effect of Moxibustion intervention on expression of Gastric epidermal growth factor receptor and extracellular signal regulated kinase 1/2 expression in rats with gastric ulcer. *Acupuncture research*. **39**:351-353.
29. Zhen, Z.J., Li, L. (2001). Effect of NF-kappa B on syndrome of inflammatory response of the whole body. *Immunology*. **17**: 314-317.