

ANTI-INFLAMMATORY EFFECT OF *ZANTHOXYLUM BUNGEANUM*-CAKE-SEPARATED MOXIBUSTION ON RHEUMATOID ARTHRITIS RATS

Xulu Lei^{1#}, Shirui Cheng^{1#}, Honglian Peng^{1#}, Qin He¹, Hongyu Zhu¹, Mengqian Xu¹, Qinqin Wang¹, Li Liu¹,
Chengshun Zhang¹, Qizhi Zhou¹, Fang Zeng¹, Jian Ying², Haiyan Yin^{1*} and Shuguang Yu^{1*}

¹Acupuncture and Tuina school, Chengdu University of Traditional Chinese Medicine, Chengdu 610075, Sichuan, China. ²Department of Oncology, Chongqing Hospital of Traditional Chinese Medicine, 400021, Chongqing, China

#These authors contribute equally to this work.

*Corresponding authors:

Haiyan Yin: E-mail: yinhaiyan@cducm.edu.cn, Shuguang Yu: E-Mail: ysg@cducm.edu.cn

Abstract

Background: *Zanthoxylum bungeanum*-cake-separated moxibustion (ZBCS-moxi), a kind of traditional therapy of moxibustion, has been used in China since 340 B.C. However, its mechanism remains unclear. So, this study was attempted to reveal the anti-inflammatory effect of ZBCS-moxi on rheumatoid arthritis (RA) rats.

Methods and Materials: Forty health SD female rats were randomly divided into 4 groups (n=10/group): control group, model group, *Zanthoxylum bungeanum*-cake-separated moxibustion group (ZBCS-moxi group) and *Aconitum carmichaeli*-cake-separated moxibustion group (ACCS-moxi group). RA model was induced by injecting 0.1 ml Freund's complete adjuvant (FCA) into the right hind paw of rats. Eleven days after FCA injection, the rats in ZBCS-moxi group received *Zanthoxylum bungeanum*- cake-separated moxibustion on Shenshu (BL23), Zusanli (ST36) acupoints and the dorsum right hind paw respectively for 3 weeks. The ACCS-moxi group was used as a positive control, while the rats were treated with *Aconitum carmichaeli*-cake-separated moxibustion on the same acupoints and courses. After a 3-week treatment, we investigated anti-inflammatory effect by measuring the paw volume, observing the pathologic morphology of synovial membranes and detecting the concentration of IL-1 β and TNF- α in serum.

Results: Compared to model group, the swollen paw volumes, the synovial hyperplasia and pannus formation of synovial membranes and the concentration of IL-1 β and TNF- α in serum decreased obviously ($P < 0.01$, $P < 0.05$) in ZBCS-moxi group, as well as in ACCS-moxi group. However, the swollen paw volumes, the synovial hyperplasia and pannus formation of synovial membranes and the concentration of IL-1 β and TNF- α in serum in ZBCS-moxi and ACCS-moxi group did not show significant differences ($P > 0.05$)

Conclusions: ZBCS-moxi displays anti-inflammatory effect on RA rats via suppressing the expression of cytokines and has similar effect to ACCS-moxi.

Key words: Anti-inflammatory effect; *Zanthoxylum bungeanum*-cake-separated moxibustion; *Aconitum carmichaeli*-cake-separated moxibustion; Rheumatoid Arthritis.

Introduction

Rheumatoid arthritis (RA) is a systemic autoimmune disorder which leads to chronic inflammation in joints, subsequent destruction of cartilage and erosion of the bone in the affected joint (Nawata et al., 2008; Gabriel et al., 2003; Sokolowska et al., 2015), affecting up to 1% of the adult population (Silman et al., 2002). Traditionally, the treatment of RA is based upon disease-modifying anti-rheumatic drugs, corticosteroid, and nonsteroidal anti-inflammatory drugs, which slow down joint damage and reduce joint swelling and pain (Hochberg et al., 45

2012; Jordan et al., 2003; NICE clinical guideline, 2012). However, the side effects of these drugs are often deleterious, which include gastrointestinal irritation, cardiovascular problems, drug dependency and so on (Scheiman, 2001).

The limited efficacy and severe adverse effects of conventionally used drugs for RA often cause patients to turn towards complementary therapies and hope such treatment might improve their symptoms. Acupuncture is emerging as adjunct therapy for the symptomatic treatment of RA (Casimiro et al., 2002). Moxibustion, as a kind of external therapy based on the theory of traditional Chinese medicine (TCM), has also frequently been used as an effective treatment for a great range of diseases like RA (Camp, 1998) and knee osteoarthritis (Lee et al., 2013). A systematic review on moxibustion for rheumatic conditions showed various kinds of moxibustion such as *Aconitum carmichaeli*-cake-separated moxibustion (ACCS-moxi), ginger-separated moxibustion and other herbal-cake-separated moxibustion on the treatment of RA (Choi et al., 2011). Studies proved that pro-inflammatory cytokines, especially TNF- α , IL-1 β , and IL-6 are expressed at higher levels in rheumatoid joints, which might be related to the mechanisms of inflammatory response (Begley et al., 1999; Tran et al., 2005). Yang HQ found that ginger-separated moxibustion interventions could reduce inflammatory reactions of the knee-joint and suppress inflammatory cytokine IL-1 and TNF- α levels of the synovial fluid in RA rabbits (Yang et al., 2013).

Zanthoxylum bungeanum-cake-separated moxibustion (ZBCS-moxi), as one of the treatment of Chinese traditional medicine, was originated from more than one thousand years ago in 340 B.C. It has been documented in *Zhou Hou Bei Ji Fang* that ZBCS-moxi can be applied to treat different kinds of pain diseases. However, whether it can generate anti-inflammatory effect or not on RA, and if so, whether it has similar effect to ACCS-moxi, has still remained unclear. Therefore, we designed following animal experiment and anticipated it would work on RA animal model.

Materials and Methods

Animals

Female Sprague-Dawley rats weighing 180 g-220 g were purchased from Experimental Animal Center of Chengdu University of Traditional Chinese Medicine. All rats were acclimatized to standard laboratory conditions (at $25 \pm 2^\circ\text{C}$, $65\% \pm 5\%$ humidity, and under pathogen-free conditions on a 12/12 h light-dark cycles) with drinking water and food available *ad libitum*. Rats were randomly divided into 4 groups: control group, model group, *Zanthoxylum bungeanum*-cake-separated moxibustion group (ZBCS-moxi group), and *Aconitum carmichaeli*-cake-separated moxibustion group (ACCS-moxi group (n=10/group)). Control group only received saline injection; Model group was administered Freund's complete adjuvant (CFA) injection; ZBCS-moxi group and ACCS-moxi group were treated by *Zanthoxylum bungeanum*-cake-separated moxibustion and *Aconitum carmichaeli*-cake-separated moxibustion respectively; beyond they were injected CFA. All experimental manipulations were undertaken in accordance with the National Institutes of Health Guide for the Care and Use of Laboratory Animals.

Induction of Arthritis by CFA

Rats in model, ZBCS-moxi and ACCS-moxi groups received an injection of 0.1 ml CFA (Sigma, St. Louis, MO, USA) in the right hind paw (Chillingworth et al., 2003; Heilborn et al., 2007), while the rats in control group were injected 0.1 ml saline in the same position.

Moxibustion Treatment

Eleven days after CFA injection, moxibustion treatment was performed on "Shenshu" (BL23), "Zusanli" (ST36) acupoints and the dorsum of swollen paw (the dorsum of right hind paw). BL23 is located in the lower border of the 2nd lumbar vertebra; ST36 is about 5 mm inferior to the capitulum fibulae and posterior-lateral to the hind limb knee joint (Yin et al., 2008). In ZBCS-moxi group, *Zanthoxylum bungeanum* cake was placed on each of the three points. A moxa-cone, which is the cone-shaped moxa wool of an apparatus-made product, was put on the cake (as shown in Figure 1), ignited from its top, moved away until it burned out, and then replaced by another new moxa-cone until the completion of 3 cones (Yang et al., 2013). The ACCS-moxi group received *Aconitum carmichaeli*-cake-separated moxibustion, as the same procedures

above. The moxibustion groups were lasted for 3 weeks (once daily, 6 treatment days per week). Additionally, the rats without receiving moxibustion stimulations in control and model groups were restricted for the same time in the same approach as the treated groups.

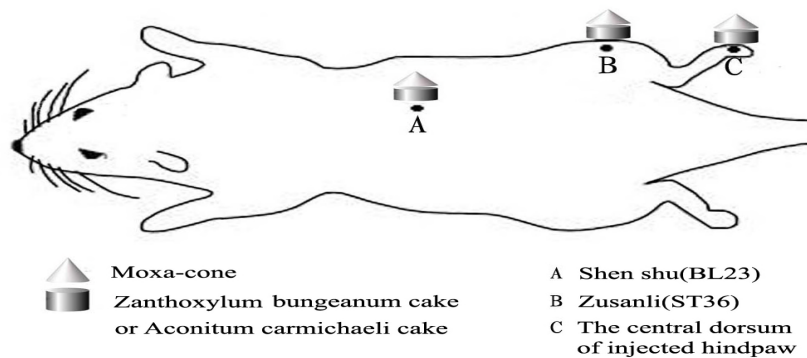


Figure 1: The points of rats where BL23, ST36 located, the central dorsum of injected hindpaw, the shape and size of moxa-cone, *Zanthoxylum bungeanum* cake or *Aconitum carmichaeli* cake are shown above.

Measurement of Paw Volume

The paw volumes of injected hind limbs were measured in all groups before CFA or saline injection, before and after treatments, using a plethysmometer. The plethysmometer consists of 2 vertical interconnected water-filled Perspex cells with precise calibration, the smaller one is used to measure volume displacement produced by dipping the rat's paw into the larger one. The mean values were calculated and plotted at each time point. All evaluations were performed by the same investigators throughout the study.

ELISA for IL-1 β and TNF- α

Blood samples were collected from the femoral artery after all treatments were finished. The blood samples were centrifuged for 10 mins at 3000 rpm and 4 °C. The supernatant was kept at -80°C before ELISA. The levels of pro-inflammatory cytokines IL-1 β and TNF- α were measured by ELISA (Neobioscience Technology Company) according to the manufacture's protocols.

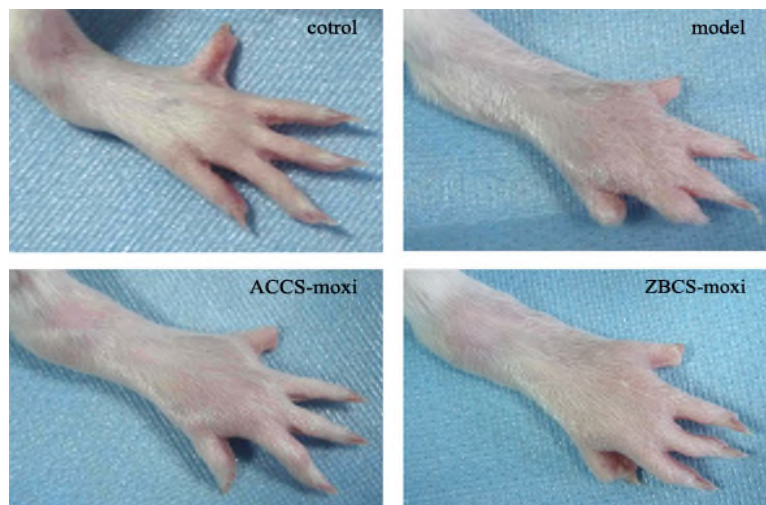


Figure 2: Representative photographs of right hind paw from control group, model group, ACCS-moxi group, and ZBCS-moxi group after 3-week treatment.

H&E Staining

After treatment for 3 weeks, synovial membranes were removed from each knee joints of the injected paws for histological observation, fixed with 4% paraformaldehyde in phosphate buffer saline (PBS, pH 7.4). The paraffin-embedded samples were cut into 4 μm sections, and stained with haematoxylin and eosin (H&E). The pathological examinations were performed by the same investigators using microscope (DP72 Olympus, Co., Ltd., Japan).

Statistical Analysis

The results were analyzed using the Statistical Package for the Social Sciences 19.0 software (SPSS, Chicago, IL, USA). The data were presented as mean±SD. Two-way ANOVA followed by Dunnett's post hoc test was used for determining the significant differences between the various groups. A level of $P<0.05$ was considered significant.

Results

Reduction of Paw Volume

We observed that the paw swelling of injected rats in ZBCS-moxi and ACCS-moxi groups was alleviated after treatments (Figure 2). We measured the paw volumes to assess the arthritic progression of CFA-induced arthritis. The paw volumes in control group nearly didn't display any changes as time went on, while the average of paw volume in model group was increased gradually (** $P<0.01$, compared with control group, Figure 3). The paw volumes of right hind limb were significantly increased in CFA-induced rats of ACCS-moxi group and ZBCS-moxi group, compared with control group before treatment (** $P<0.01$, Figure 3). The rats treated by *Zanthoxylum bungeanum*-cake-separated and *Aconitum carmichaeli*-cake-separated moxibustion displayed slight decrease of injected paws after treatment for one week. The paw volumes of CFA-induced rats in treated group appeared an interesting inhibition after treatment for 2 weeks, but no significant differences appeared when compared with the untreated arthritic rats. After treatment for 3 weeks, both ZBCS-moxi group and ACCS-moxi group demonstrated a clear evidence of reduction of paw swelling, showing a statistically significant attenuation (** $P<0.01$, Figure 3).

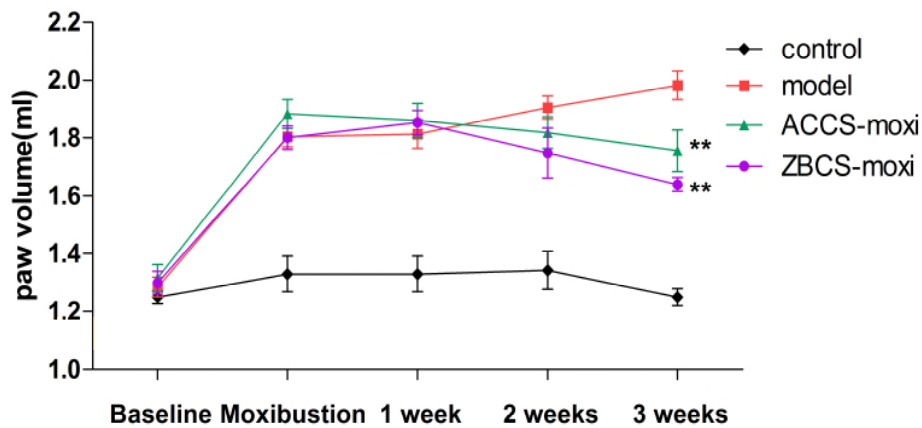


Figure 3: Effect of moxibustion on the swelling paw in CFA-induced arthritis rats. Both ACCS-moxi group and ZBCS-moxi group

demonstrated a clear evidence of reduction of paw volume after 3-week treatment (** $P < 0.01$, compared with model group).

Inhibition of Synovial Hyperplasia

The sections of control group, in which rats were injected with saline, revealed little or no signs of inflammation, no synovial hyperplasia (Figure 4, control). And those in model group, the rats injected with CFA without any treatment, displayed notable synovial hyperplasia, apparent pannus formation and massive accumulation of inflammatory substances (Figure 4, model). After a 3-week treatment, the synovial membrane of rats in ACCS-moxi and ZBCS-moxi groups revealed mild inhibition of inflammation, synovial hyperplasia or pannus formation in comparison to arthritic rats (Figure 4, ACCS-moxi, ZBCS-moxi).

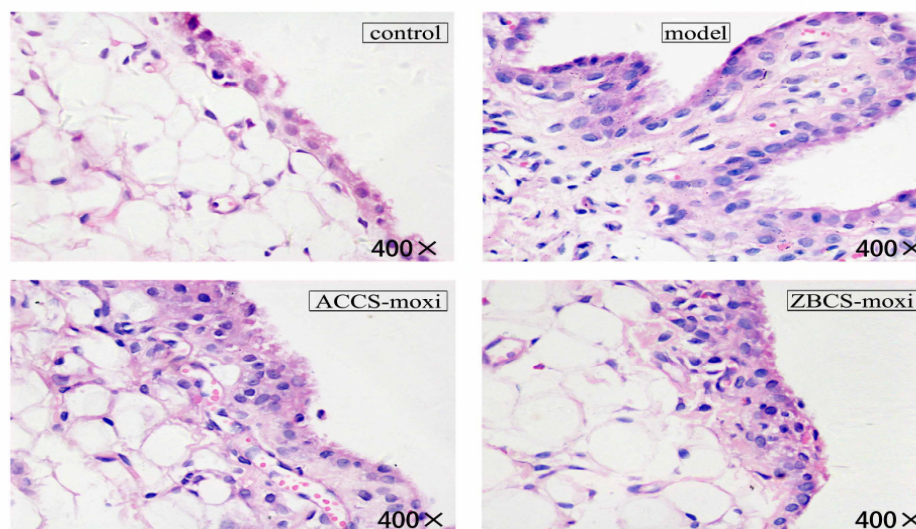


Figure 4: H&E staining of Synovial Membrane. Control group: note normal organization, lack of inflammatory cell infiltration. Model group: notable synovial hyperplasia, apparent pannus formation, massive accumulation of inflammatory cells. ACCS-moxi group and ZBCS-moxi group: mild inhibition of inflammation, synovial hyperplasia or pannus formation.

Suppression of IL-1 β and TNF- α in Serum

The model group indicated a significant increase in IL-1 β release in comparison with the control group (** $P < 0.01$, Figure 5). Both ACCS-moxi group and ZBCS-moxi group produced a significant reduction of IL-1 β than that in those models (** $P < 0.01$, Figure 5). Accompanying with the suppression of IL-1 β , the levels of TNF- α were measured (Figure 5). Increased levels of TNF- α in model group respect to control group were observed (** $P < 0.01$, Figure 5). The *Zanthoxylum bungeanum*-cake-separated moxibustion in ZBCS-moxi group was able to reduce TNF- α levels (** $P < 0.05$), as well as the ACCS-moxi group (* $P < 0.05$). No significant differences appeared in the concentration of IL-1 β and TNF- α between the two groups.

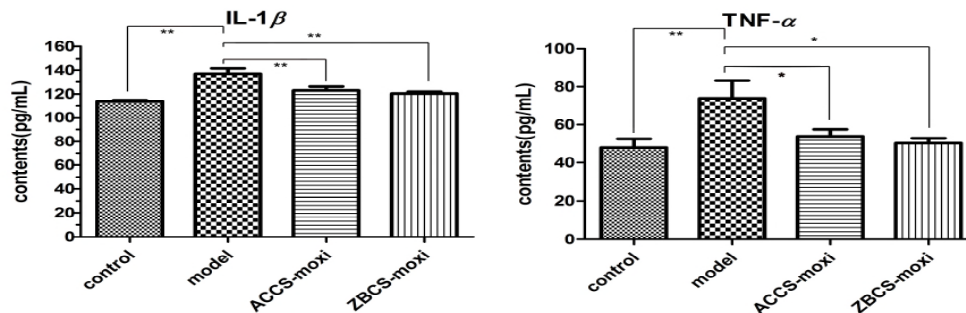


Figure 5: Effect of moxibustion on the levels of serum IL-1 β and TNF- α in CFA-induced arthritis rats. ** P <0.01, * P <0.05, as compared with the other group. No statistical differences between ACCS-moxi group and ZBCS-moxi.

Discussion

To our knowledge, this study is the first attempt to assess the anti-inflammatory effects of ZBCS-moxi on CFA rat models. In this research, the results indicated that ZBCS-moxi could significantly suppress the paw swelling, inhibit synovial hyperplasia and reduce the levels of IL-1 β and TNF- α in serum and has similar effect to ACCS-moxi. It suggested that ZBCS-moxi would be supposed to be adopted to treat RA in clinic like other types of moxibustion, such as ginger-separated moxibustion (Xie et al., 2008; Shen, 2001), and *Aconitum carmichaeli*-cake-separated moxibustion (Sun et al., 2008; Li et al., 2006), which were demonstrated to be effective for treating rheumatic symptoms.

The ZBCS-moxi is a kind of special traditional moxibustion, which uses the heat generated by burning herbal preparations containing *Artemisia vulgaris* to stimulate acupoints (Choi et al., 2011). *Zanthoxylum bungeanum*, also known as Pepper, is a traditional Chinese herb, which is prescribed to treat inflammatory disorders in previous studies (Yang et al., 2007; Yang et al., 2013). Previous phytochemical investigations have revealed piperine, a main component in *Zanthoxylum bungeanum*, has demonstrated its anti-inflammatory and immuno-modulatory activities (Sunila et al., 2004; Pathak et al., 2007; Kim et al., 2009; Kumar et al., 2007). Our results showed that ZBCS-moxi treatment could obviously suppress the paw inflammation associated with the disease, inhibit synovial hyperplasia and demonstrate a significant drop in the levels of IL-1 β and TNF- α that played a decisive role in the progression of RA (Qi et al., 2014; Gravallesse et al., 2000; Sakthiswary et al., 2013), and that was in accord with previous researches about moxibustion (Yang et al., 2013).

In previous researches, most of moxibustion studies focused on ginger-separated moxibustion and ACCS-moxi (Shen, 2001; Sun et al., 2008; Li et al., 2006), while ZBCS-moxi, as one of the traditional moxibustion, could not get enough attention. According to this study, it shows that the anti-inflammatory influences of ZBCS-moxi cannot be ignored. In this study, we took the ACCS-moxi, which was a frequently-used therapeutic measure of rheumatic arthritis, as the positive control group, and the similar anti-inflammatory effect was found between ZBCS-moxi and ACCS-moxi. However, that whether ZBCS-moxi or ACCS-moxi would produce better effect on RA than moxibustion without *Zanthoxylum bungeanum*-cake or *Aconitum carmichaeli*-cake is waiting for providing evidences in future work.

In conclusion, we investigated the anti-inflammatory effect of ZBCS-moxi on rheumatoid arthritis rats for the first time and found that ZBCS-moxi could decrease the paw swelling and inhibit the expression of IL-1 β and TNF- α in RA rats, which might contribute to its anti-inflammatory effect on RA. Our results indicated that ZBCS-moxi is effective in improving the symptoms of RA rats through suppressing the expression of cytokines, which could be used as an alternative therapy and this study provides an experimental basis for the clinical application of *Zanthoxylum bungeanum*-cake-insulated moxibustion.

Conflict of Interests: The authors declare that there is no conflict of interests.

Acknowledgments

This study was supported by the National Basic Research Program of China (973 Program, 2015CB554504), Science and Technology Department of Sichuan Province (2014JY0031), the Scientific Research Foundation of the Education Department of Sichuan Province (14ZA0081) and Chongqing Natural Science Foundation (CSTC2011jjA1388).

References

1. Begley, C.G., and Nicola, N.A. (1999). Resolving conflicting signals: cross inhibition of cytokine signaling pathways. *Blood*, 93:1443-1447.
2. Brennan, F.M., and McInnes, I.B. (2008). Evidence that cytokines play a role in rheumatoid arthritis. *J. Clin. Invest.* 118:3537-3545.
3. Camp, A.V. (1998). Acupuncture for Rheumatology Problems. *Medical Acupuncture*, 13: 801- 804.
4. Casimiro, L., Brosseau, L., Milne, S., Robinson, V., Wells, G., and Tugwell, P. (2002). Acupuncture and electroacupuncture for the treatment of RA. *Cochrane Database Syst. Rev.*, CD003788.
5. Chillingworth, N.L., and Donaldson, L.F. (2003). Characterisation of a Freund's complete adjuvant-induced model of chronic arthritis in mice. *J Neurosci. Methods*, 128:45-52.
6. Choi, T.Y., Kim, T.H., Kang, J.W., Lee, M.S., and Ernst, E. (2011). Moxibustion for rheumatic conditions: a systematic review and meta-analysis. *Clin. Rheumatol*, 30:937-945.
7. Excellence National Institute for Health and Clinical. Rheumatoid arthritis: the management of rheumatoid arthritis in adults. NICE clinical guideline 79 (2012). Available at: <http://www.nice.org.uk/nicemedia/pdf/CG79NICEGuideline.pdf>.
8. Gabriel, S.E., Crowson, C.S., Kremers, H.M., Doran, M.F., Turesson, C., O'Fallon W.M., and Matteson, E.L. (2003). Survival in rheumatoid arthritis: a population - based analysis of trends over 40 years. *Arthritis Rheum.*, 48:54-58.
9. Gravallese, E.M., and Goldring, S.R. (2000). Cellular mechanisms and the role of cytokines in bone erosions in rheumatoid arthritis. *Arthritis Rheum.*, 43:2143-2151.
10. Heilborn, U., Berge, O.G., Arborelius, L., and Brodin, E. (2007). Spontaneous nociceptive behaviour in female mice with Freund's complete adjuvant-and carrageenan-induced monoarthritis. *Brain Res.*, 1143:143-149.
11. Hochberg, M.C., Altman, R.D., April, K.T., Benkhalti, M., Guyatt, G., McGowan, J., Towheed, T., Welch, V., Wells, G., and Tugwell, P. (2012). American college of rheumatology 2012 recommendations for the use of nonpharmacologic and pharmacologic therapies in osteoarthritis of the hand, hip, and knee. *Arthritis Care Res. (Hoboken)*, 64:465-474.
12. Jordan, K.M., Arden, N.K., Doherty, M., Bannwarth, B., Bijlsma, J.W., Dieppe, P., Gunther, K., Hauselmann, H., Herrero-Beaumont, G., Kaklamanis, P., Lohmander, S., Leeb, B., Lequesne, M., Mazieres, B., Martin-Mola, E., Pavelka, K., Pendleton, A., Punzi, L., Serni, U., Swoboda, B., Verbruggen, G., Zimmerman-Gorska, I., and Dougados, M. (2003). EULAR Recommendations 2003: An evidence based approach to the management of knee osteoarthritis: Report of a Task Force of the Standing Committee for International Clinical Studies Including Therapeutic Trials (ESCISIT). *Ann. Rheum. Dis.*, 62:1145-1155.
13. Kim, S.H., and Lee, Y.C. (2009). Piperine inhibits eosinophil infiltration and airway hyperresponsiveness by suppressing T cell activity and Th2 cytokine production in the ovalbumin-induced asthma model. *J. Pharm. Pharmacol.*, 61:353-359.
14. Kumar, S., Singhal, V., Roshan, R., Sharma, A., Rembhotkar, G.W., and Ghosh, B. (2007). Piperine inhibits TNF- α induced adhesion of neutrophils to endothelial monolayer through suppression of NF- κ B and I κ B kinase activation. *Eur. J. Pharmacol.*, 575:177-186.
15. Li, J.W., Liu, J.M., Ma, Z.Y., Xiong, Y.Y., Feng, Y.B., Xiang, S.Y., Zhang, J., Peng, H.Z. (2006). Clinical observation on treatment of rheumatoid arthritis with cake-separated mild moxibustion combined with Western medicine. *Zhongguo Zhen Jiu*, 26:192-194.
16. Lee, S., Kim, K.H., Kim, T.H., Kim, J.E., Kim, J.H., Kang, J.W., Kang, K.W., Jung, S.Y., Kim, A.R., Park, H.J., Shin, M.S., Hong, K.E., Song, H.S., Choi, J.B., Kim, H.J., and Choi, S.M. (2013). Moxibustion for treating knee osteoarthritis: study protocol of a multicentre randomised controlled trial. *BMC Complement. Altern. Med.*, 13:1-9.
17. Nawata, M., Saito, K., Nakayama, S., and Tanaka, Y. (2008). Discontinuation of infliximab in rheumatoid arthritis patients in clinical remission. *Mod. Rheumatol.*, 18:460-464.

18. Pathak, N., and Khandelwal, S. (2007). Cytoprotective and immunomodulating properties of piperine on murine splenocytes: An in vitro study. *Eur. J. Pharmacol.*, 576:160-170.
19. Qi, J.Y., Ye, X.L., Ren, G., Kan, F., Zhang, Y., Guo, M., Zhang, Z., and Li, D. (2014). Pharmacological efficacy of anti-IL-1 β scFv, Fab and full-length antibodies in treatment of rheumatoid arthritis. *Mol. Immunol.*, 57:59-65.
20. Sakthiswary, R., and Das, S. (2013). The Effects of TNF α Antagonist Therapy on Bone Metabolism in Rheumatoid Arthritis: A Systematic Review. *Curr. Drug Targets*, 14:1552-1557.
21. Scheiman, J.M. (2001). The impact of nonsteroidal anti-inflammatory drug-induced gastropathy. *The Am. J. Manag. Care*, 7:S10-14.
22. Shen, Y.Q. (2001). Treatment of 150 Cases of Arthralgia Syndrome with Moxibustion Therapy. *Zhongguo Zhen Jiu*, 8:31.
23. Silman, A.J., and Pearson, J.E. (2002). Epidemiology and genetics of rheumatoid arthritis. *Arthritis Res.*, 4:S265-S272.
24. Sokolowska, B., Czerwos, L., Hallay-Suszek, M., Sadura-Sieklucka, T., and Księżopolska-Orłowska, K. (2015). Posturography in patients with rheumatoid arthritis and osteoarthritis. *Adv. Exp. Med. Biol.*, 833:63-70.
25. Sunila, E.S., and Kuttan, G. (2004). Immunomodulatory and antitumor activity of Piper longum Linn and piperine. *J. Ethnopharmacol.*, 90:339-346.
26. Sun, K., Yang, J., and Shen, D.K. (2008). Clinical observation on treatment of primary knee osteoarthritis of liver and kidney deficiency type with Aconite cake-separated moxibustion. *Zhongguo Zhen Jiu*, 28:87-90.
27. Tran, C.N., Lundy, S.K., and Fox, D.A. (2005). Synovial biology and T cells in rheumatoid arthritis. *Pathophysiology*, 12:183-189.
28. Xie, X.X., and Lei, Q.H. (2008). Observation on therapeutic effect of the spreading moxibustion on rheumatoid arthritis. *Zhongguo Zhen Jiu*, 28:730-732.
29. Yang, H.Q., Liu, X.G., Yang, X., Chen, T., Yu, S.G. (2013). Effect of different types of moxibustion intervention on expression of inflammatory cytokines IL-1 and TNF-alpha in rabbits with rheumatoid arthritis. *Zhen Ci Yan Jiu*, 38:134-139.
30. Yang, X., Li, J.S., Yang, S.Q., Zhang, X.X., Zhang, T.S., Zhou, H.Y., and Liu, X.G. (2007). Influence of moxibustion on JAK-STAT signal transduction pathways of synovial cells in rheumatoid arthritis rabbits. *Zhen Ci Yan Jiu*, 32:75-82.
31. Yang, X., Liu, X.G., Wang, Y., Yang, S.Q., and Jin, R.J. (2013). Effects of moxibustion intervention on inflammatory reactions and expression of suppressor of cytokine signaling proteins of synovium cells in rheumatoid arthritis rabbits. *Zhen Ci Yan Jiu*, 38:129-133.
32. Yin, C.S., Jeong, H.S., Park, H.J., Baik, Y., Yoon, M.H., Choi, C.B., and Koh, H.G. (2008). A proposed transpositional acupoint system in a mouse and rat model. *Res. Vet. Sci.*, 84:159-165.